



Lethal Arrhythmias: Advanced Rhythm Interpretation

This course has been awarded three (3) contact hours.

Copyright © 2015 by RN.com
All Rights Reserved

Reproduction and distribution of these materials is prohibited without the express written authorization of RN.com.

First Published: January 14, 2003
Course Expires: October 31, 2019

Acknowledgments

RN.com acknowledges the valuable contributions of...

Original Authors:

Suzan Miller-Hoover, DNP, RN, CCNS, CCRN

Disclaimer

RN.com strives to keep its content fair and unbiased. The author(s), planning committee, and reviewers have no conflicts of interest in relation to this course. There is no commercial support being used for this course. Participants are advised that the accredited status of RN.com does not imply endorsement by the provider or ANCC of any commercial products mentioned in this course.

There is "off label" usage of medications discussed in this course.

You may find that both generic and trade names are used in courses produced by RN.com. The use of trade names does not indicate any preference of one trade named agent or company over another. Trade names are provided to enhance recognition of agents described in the course.

Note: All dosages given are for adults unless otherwise stated. The information on medications contained in this course is not meant to be prescriptive or all-encompassing. You are encouraged to consult with physicians and pharmacists about all medication issues for your patients.

Purpose

The purpose of Lethal Arrhythmias: Advanced Rhythm Interpretation is to build a foundation for recognizing and treating lethal rhythms. After reviewing basic anatomy, physiology, conduction pathways, and ECG rhythm interpretation; case studies will help you apply what has been learned.

Learning Objectives

After successful completion of this course, you will be able to:

1. Delineate the anatomy and physiology of the heart
2. Describe the basic electrophysiology of the heart
3. Identify and interpret an ECG waveform
4. Identify five lethal arrhythmias
5. Define the initial treatment of the five lethal arrhythmias
6. Describe treatment utilizing a cardiac defibrillator/external pacemaker

Introduction

As nurses, we need to respond appropriately in the event of a lethal arrhythmia. When a patient suffers a lethal arrhythmia every second counts. Are you ready? Will you be able to make the quick decisions necessary to save your patient's life? Although patients with known cardiac disease suffer the greatest number of lethal arrhythmias, arrhythmias may occur with any patient on any floor at any time.

Not all the arrhythmias discussed in this module are lethal. It is the heart's response to the arrhythmia which determines symptomology. It is imperative that nurses understand the basic anatomy and physiology of the heart; and the conduction pathway in order to respond appropriately to the arrhythmias seen on the monitor.

In this course, you will learn about **premature ventricular contractions, ventricular tachycardia, ventricular fibrillation, pulseless ventricular tachycardia, pulseless electrical activity, asystole, agonal rhythms, and supraventricular tachycardia**. You will learn how to quickly interpret the rhythm, and to prioritize your nursing interventions. The treatments for each of these arrhythmias will be discussed as well as the most common types of defibrillators currently in use.

While most of this information can be used for all populations, the normal values referred to in this module are adult. For pediatric and neonatal normal values refer to the standard values utilized by your institution.

Standard lead selection, placement, and tracings are not covered in this course. If you need to review these topics, please refer to the *Telemetry Interpretation* course on RN.com.

Cardiac Anatomy

Self-assessment:

Can you identify the chambers of the heart? Take a few minutes to fill in the blanks of this diagram.

Can you identify all of these?

Right atria

Left atria

Right ventricle

Left ventricle

Tricuspid valve

Aortic valve

Mitral valve

Pulmonary valve

Superior vena cava

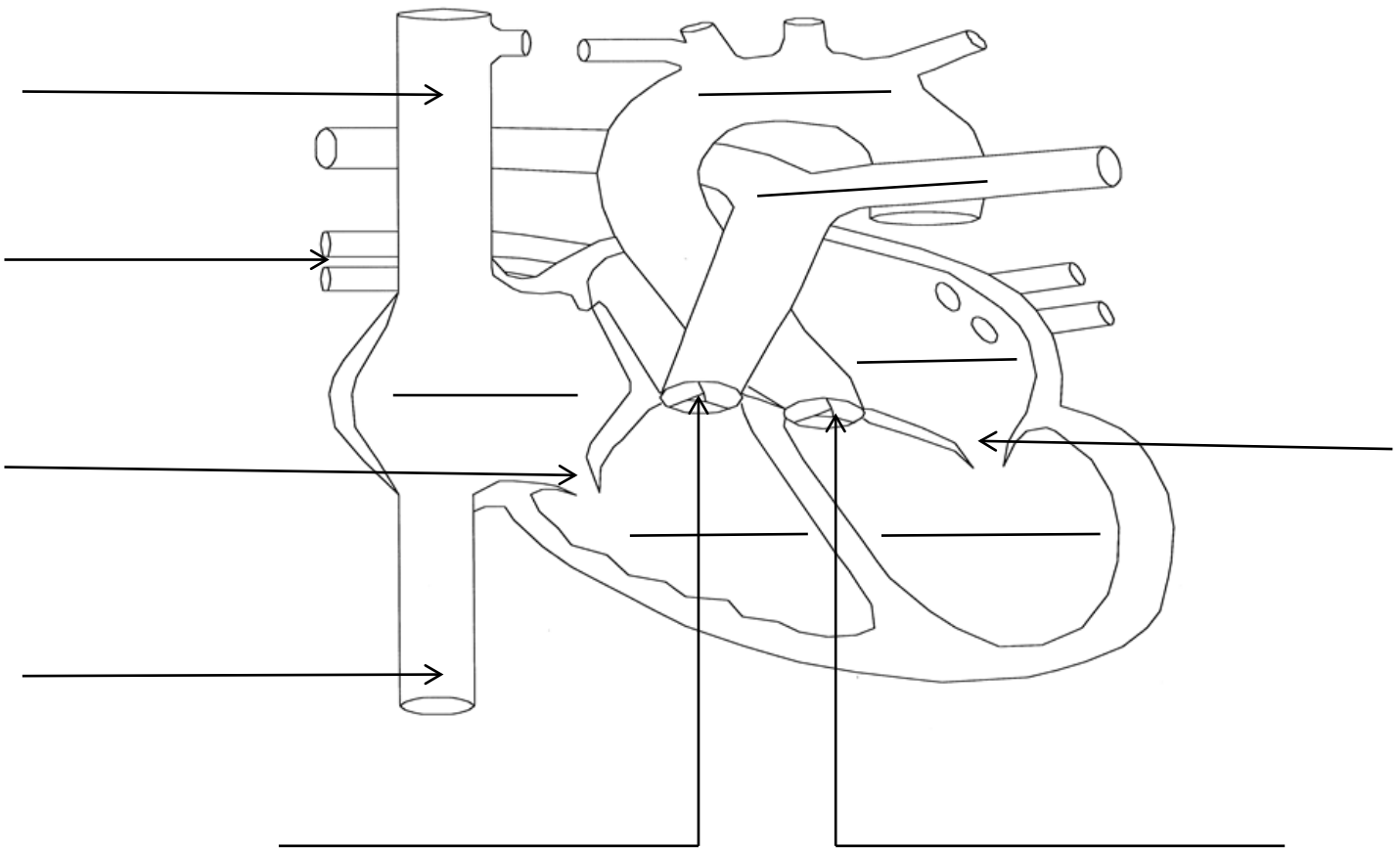
Inferior vena cava

Aorta

Pulmonary veins

Pulmonary artery

How did you do?



Cardiac Physiology:

In addition to knowing the anatomy of the heart, one must understand how the chambers and valves work together to sustain cardiac output; even during times of stress or when arrhythmias are present.

Cardiac Output:

Cardiac output (CO) is defined as the amount of blood expelled from the ventricles during systole. Cardiac output is influenced by preload, afterload, and contractility. The formula for determining CO is: Heart rate X stroke volume. Did you know that 60-70% of the total volume of blood is in ventricles during diastole?

The components of CO are defined as:

- Preload: Volume of blood in vascular system
- Afterload: Amount of systemic vascular resistance or blood pressure
- Contractility: The ability of the ventricles to contract efficiently

Any arrhythmia that disrupts any of the three components of CO will ultimately diminish CO, resulting in a symptomatic patient.

Did you know that one of the major contributors to sustained CO is the amount of blood ejected by the atria during systole? This phenomena is referred to as the “atrial kick”.

Any arrhythmia that causes the atria not to contract will diminish the CO, resulting in a symptomatic patient.

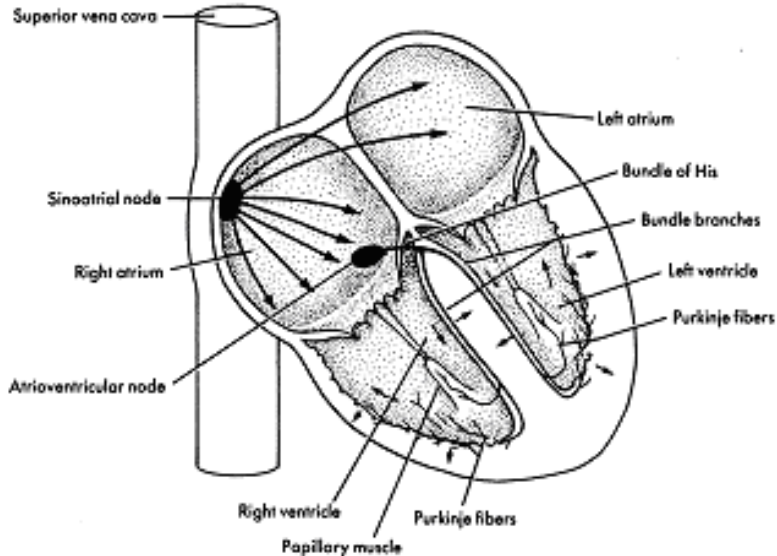
Self-Assessment:

A patient presents in the unit with a heart rate of 40. What else would you want to know about this patient before you call the physician?

Consider: It is imperative to ascertain if the patient is symptomatic. What is his/her blood pressure, capillary refill, pulse strength, and cognitive level? Would you treat the bradycardia if the patient showed no signs of decompensation?

Cardiac Conduction:

Understanding the normal cardiac conduction system is imperative to decoding the dysfunctional conduction system.



Basic Electrophysiology - Depolarization & Repolarization

In a cardiac cell, two primary chemicals provide the electrical charges: sodium (Na^+) and potassium (K^+). In the resting cell, most of the potassium is on the inside, while most of the sodium is on the outside. This results in a negatively charged cell at rest, the interior of the cardiac cell is negative or polarized at rest. When depolarized, the interior cell becomes positively charged and the cardiac cell will contract.

Since the polarized or resting cell has the negative charge at rest, depolarization occurs when sodium moves across the cell membrane into the cell, positively charged. As depolarization occurs, the change in membrane voltage triggers contraction of the cell.

Depolarization moves a wave through the myocardium. As the wave of depolarization stimulates the heart's cells, they become positive and begin to contract. This cell-to-cell conduction of depolarization through the myocardium is carried by the fast moving sodium ions.

Repolarization is the return of electrical charges to their original state. This process must happen before the cells can be ready to conduct again.

The adjacent represents normal cardiac rhythm and how it relates to the depolarization and repolarization of the cardiac cells.

Test Yourself

A positively charged cell occurs because which electrolyte enters the cell?

Answer:

Sodium

Material Protected by Copyright

Rationale: Since the polarized or resting cell has the negative charge at rest, depolarization occurs when sodium moves across the cell membrane into the cell, positively charged. As depolarization occurs the change in membrane voltage triggers contraction of the cell.

The Cardiac Conduction System

The specialized electrical cells in the heart are arranged in a system of pathways called the conduction system. These specialized electrical cells and structures guide the wave of myocardial depolarization.

The conduction system consists of the **sinoatrial node** (SA node), **atrioventricular node** (AV node), **bundle of His** (also called the AV Junction), **right and left bundle branches**, and **purkinje fibers**.

The Sinoatrial (SA) Node

The sinoatrial node (also called the SA node or sinus node) is a group of specialized pacemaker cells located in the posterior wall of the right atrium near the junction of the superior vena cava. The SA node depolarizes or paces more rapidly than any other part of the conduction system. It sets off impulses that trigger atrial depolarization and contraction.

The SA node normally fires at a rate of 60-100 beats per minute.

After the SA node fires, a wave of cardiac cells begin to depolarize. Depolarization occurs throughout both the right and left atria (similar to the ripple effect when a rock is thrown into a pond). This impulse travels through the atria by way of inter-nodal pathways down to the AV node.

The Atrioventricular (AV) Node and AV Junction

The next area of conductive tissue along the conduction pathway is at the site of the atrioventricular (AV) node. This node is a cluster of specialized cells located in the lower portion of the right atrium, above the base of the tricuspid valve. The AV node itself possesses no pacemaker cells.

The AV node has two functions. The first function is to DELAY the electrical impulses in order to allow the atria time to contract and complete the filling of the ventricles. The AV node is a decremental conduction pathway; meaning the more frequently the node is stimulated the slower it conducts. This is the property of the AV node that prevents rapid conduction to the ventricle in cases of rapid atrial rhythms, such as atrial fibrillation or atrial flutter (Patterson & Scherlag, 2006). The second function is to receive an electrical impulse and conduct it down to the ventricles via the AV junction and bundle of His.

The Bundle of His

After passing through the AV node, the electrical impulse enters the bundle of His. The bundle of His is located in the upper portion of the interventricular septum and connects the AV node with the two bundle branches.

If the SA node becomes diseased or fails to function properly, the bundle of His has pacemaker cells that are capable of discharging at an intrinsic rate of 40-60 beats per minute.

The AV node and the bundle of His are referred to collectively as the AV junction. The bundle of His conducts the electrical impulse down to the right and left bundle branches. The bundle branches further divide into purkinje fibers.

Test Yourself

The AV junction has the capability to slow the rate of atrial impulses that travel through the AV node to the Bundle of His. This capability is called?

- a. Incremental conduction pathway
- b. Decremental conduction pathway
- c. Ventricular conduction pathway
- d. Atrial conduction pathway

Rationale:

The AV node is a decremental conduction pathway; meaning the more frequently the node is stimulated the slower it conducts. This is the property of the AV node that prevents rapid conduction to the ventricle in cases of rapid atrial rhythms, such as atrial fibrillation or atrial flutter

The Purkinje Fibers

At the terminal ends of the bundle branches, smaller fibers distribute the electrical impulses to the muscle cells, which stimulate contraction. This web of fibers is called the Purkinje fibers.

The Purkinje fibers penetrate 1/4 to 1/3 of the way into the ventricular muscle mass and then become continuous with the cardiac muscle fibers. The electrical impulse spreads rapidly through the right and left bundle branches to the Purkinje fibers stimulating ventricular contraction or systole.

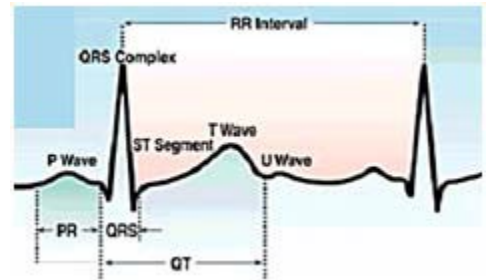
The Purkinje fibers within the ventricles also have intrinsic pacemaker ability. This third and final pacemaker site of the myocardium can only pace at a **rate of 20-40 beats per minute**.

ECG Waveforms

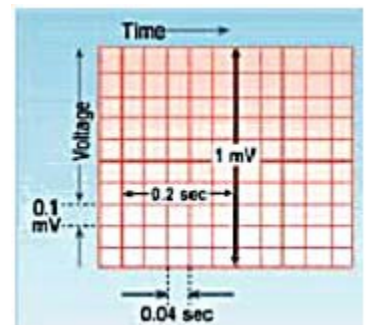
Normal ECG Waveforms and Intervals

ECG paper is graph paper that is made up of small squares and larger, heavy-lined squares. The smallest squares are one millimeter wide and one millimeter high. There are five small squares between the heavier lines.

On the ECG graph paper, time is measured in seconds along the horizontal axis. Each small square is 1 mm in length and represents 0.04 seconds. Each larger square is 5 mm in length representing 0.2 seconds.



*The diagrams illustrate the configuration of **ECG Graph Paper** and where to measure the components of the **ECG Waveform**.*



ECG Voltage

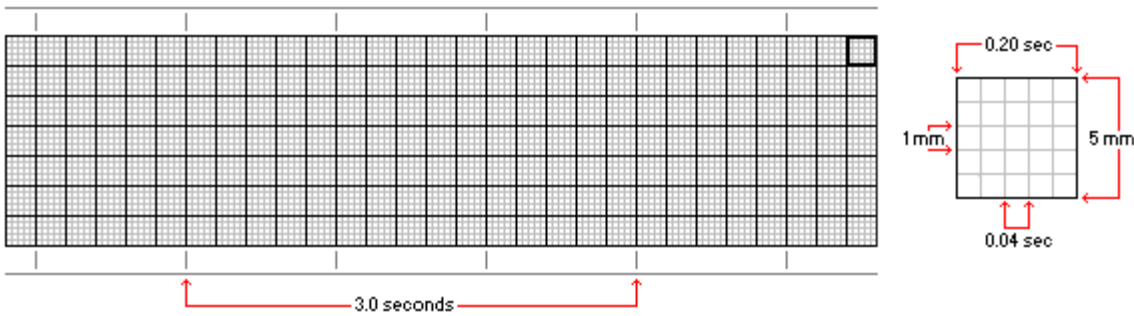
Voltage or amplitude is measured along the vertical axis. The size or amplitude of a waveform is measured in millivolts or millimeters. One small square on the vertical axis is equal to 1 millimeter (mm). When properly calibrated, a one-millivolt electrical signal will produce a deflection measuring exactly 10mm in height.

Evaluation of an ECG Rhythm Strip

To evaluate an ECG rhythm strip, print a strip of at least a 6-second duration. This type of ECG print out will be adequate for the majority of rhythm interpretations. A continuous longer strip can always be printed especially when unusual rhythms present and require a closer inspection.

When an ECG strip is printed, heart rate information printed at the top of the strip may or may not be accurate information. Therefore, you should know how to calculate the heart rate from the ECG recording. There are numerous methods used to calculate a heart rate.

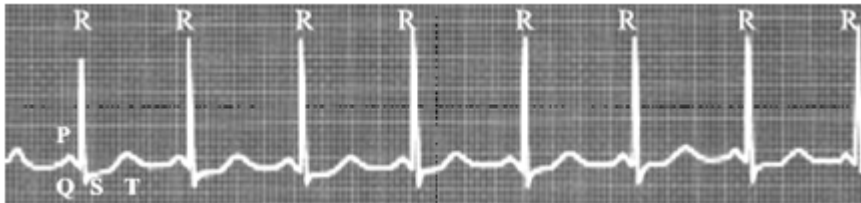We will briefly review three of the most common methods for heart rate calculation.



The Six Second Method of ECG Rate Determination

The six second method is best used with regular rhythms and provides a rough estimate (but not precise) of heart rate.

Print a 6-second strip. Count the number of R waves in a 6-second strip and multiply by 10. For example, if there are seven (7) R waves in a 6-second strip, the heart rate is approximately 70. ($7 \times 10 = 70$)

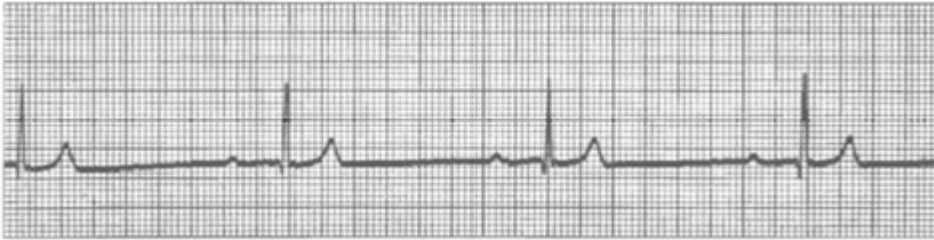


The above strip is a six second strip. Using the Six Second Strip Method, what is the approximate heart rate?

- A. 70
- B. 80**
- C. 90
- D. 100

Large Box Method of Rate Determination

Count the number of large squares between two consecutive R waves. Divide this number into 300 for a ventricular rate. For example, if there are four large squares between regular QRS complexes, the heart rate is 75 ($300/4=75$). For an atrial rate, count the number of large boxes between two consecutive P waves and also divide into 300.

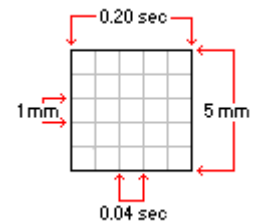


Using the large box method, what is the rate for the above rhythm strip?

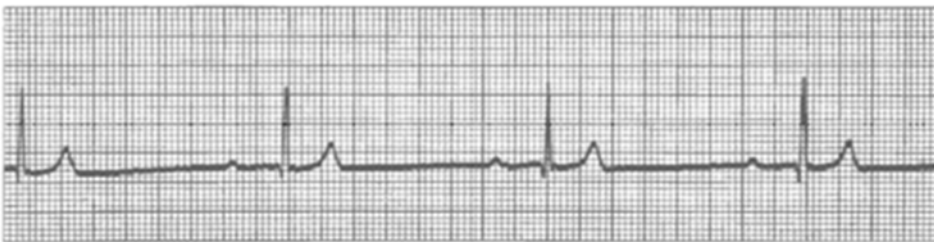- A. 32
- B. 37**
- C. 45
- D. 52

Small Box Method of Rate Determination

This method also uses an "R to R" or "P to P" measurement, but is more precise because we use the smaller ECG boxes to help us calculate the heart rate. To calculate the ventricular rate, count the number of small boxes between two consecutive R waves and divide into 1500. To calculate the atrial rate, count the number of small boxes between two consecutive P waves and divide into 1500.



If you only have a short rhythm strip (less than 6 seconds) use either the Large Box Method or the Small Box Method.



Using each of the three methods listed above, calculate the rate for the above rhythm strip.

- A. Six second method: 40
- B. Big box method: 37
- C. Small box method: 37.5**

Standardized Process for ECG Interpretation:

The ECG tracing provides a variety of clues as to what is happening within the heart. These clues include heart rate, regularity or irregularity of the rhythm, interval measurements and characteristics of each individual waveform. The key to successful ECG interpretation is using a standardized method for reviewing the strip and paying attention to the details.

Remember to print a 6-second strip (or longer) and to use your calipers for measurements each time you begin an interpretation. Follow the six basic steps each time rhythm interpretation is performed.

Six Basic Steps for Rhythm Interpretation

1. **Rate:** (Calculate the heart rate)
2. **Regularity:** (Measure the regularity or rhythm of the R waves)
3. **P-wave Examination:** Is there one P wave before each QRS?
4. **P to R Interval:** (Measure the P to R interval)
5. **QRS Width:** (Measure the duration of the QRS complex)

Rhythm Interpretation

Step 1 - Find the Rate

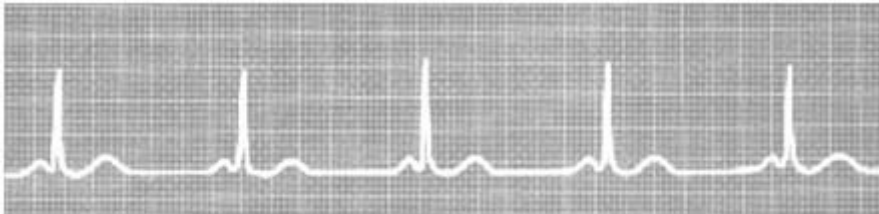
Calculate both the atrial and ventricular rates.

Normal Findings:

- The HR should be between 60-100 beats/minute.
- The atrial rate should be the same as the ventricular rate.

Abnormal Findings:

- Heart rates less than 60 beats/minute are bradycardiac.
- Heart rates greater than 100 beats/minute are tachycardiac.



Step 2 - Regularity or Pattern of the Rhythm

Step 2 is the assessment of the regularity of the rhythm. Is it regular or irregular?

To assess regularity, place the legs of your calipers on two consecutive R waves. This is your “R to R” or “R-R” interval. Without moving the width of the calipers, march through the rhythm as you travel from R wave to R wave. Do the R waves follow a regular pattern? If so, the ventricular rhythm is called **regular rhythm**.

If the R-R interval varies in the number of ECG small boxes between them, the ventricular rhythm is **irregular**.

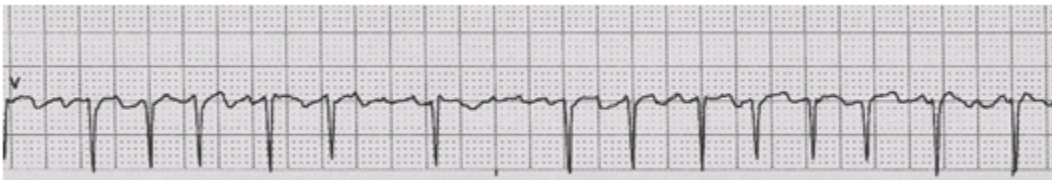
Do the same type of assessment with the atrial rhythm. Put your calipers at the beginning (or upslope) of a P wave. Put the other end of your caliper at the beginning of the next P wave. This is the P-P interval. Lift your calipers and begin marching through the strip looking for the pattern of regularity of the P waves. If the AV junction is functioning properly, the P-P interval will be regular.

Normal Findings:

- The R-R intervals are regular.
- The P-P intervals are regular.
- There is one P for every QRS.

Abnormal Findings:

- The R-R intervals are irregular.
- The P-P intervals are irregular.
- There is more than one P for each QRS.



Step 3 - P Wave Examination

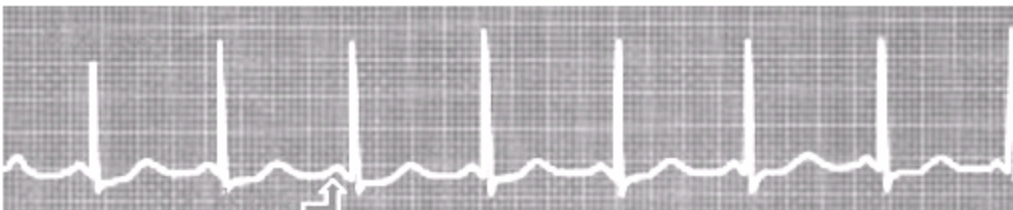
Step 3 is the examination of the P wave. First, you must go on a “P hunt” and find the P waves. Once you have identified them, assess their characteristics.

Normal Findings:

- P waves should be regular.
- P waves have a symmetrical shape, usually upright and rounded.
- P waves should all look uniform and should point in the same direction.

Abnormal Findings:

- P wave is not followed by a QRS complex.
- There are more/less P waves than QRS complexes (there should be one P for every QRS or a 1:1 relationship).



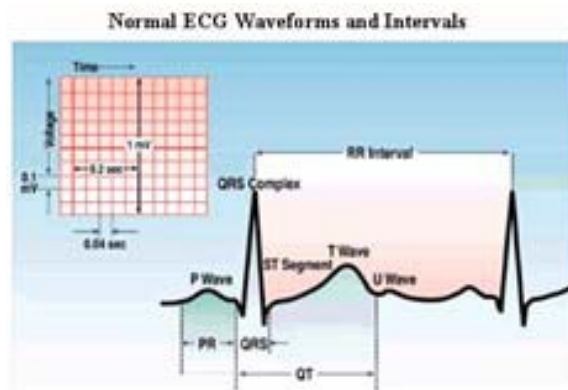
Nursing Tip:

Many healthy individuals have heart rates below 60 beats/minute, especially athletes. Always check the patient’s blood pressure, peripheral perfusion, and pulse strength to assess the hemodynamic response to a slow or fast heart rate, especially when there is a rise or fall of greater than 20 beats/minute.

Step 4 - P to R Interval

Remember that the P to R interval represents the time it takes an impulse to travel from the atria through the AV node. The P to R interval is measured from the beginning of the P wave to the beginning of the QRS complex.

This can be a bit confusing as you might think it is a measurement from the beginning of the P wave to the beginning of the Q wave, or in the event of no Q wave; use the beginning of the R wave.



Normal Findings:

- The PR interval (or time travel from SA to AV nodes) is between 0.12 to 0.20 seconds.
- The PR intervals are constant throughout the rhythm.

Abnormal Findings:

- The PR interval is greater than 0.20 seconds (this might indicate delayed travel time from SA to AV node).
- The PR interval is irregular in measurement (irregular or varying PR intervals may indicate some type of SA-AV conduction problem and possible conduction heart block).

Note: Some individuals have a benign delayed PR interval called sinus dysrhythmia caused by their effort of breathing. This is especially true with pediatric and neonatal patients.

Step 5a - QRS Complex

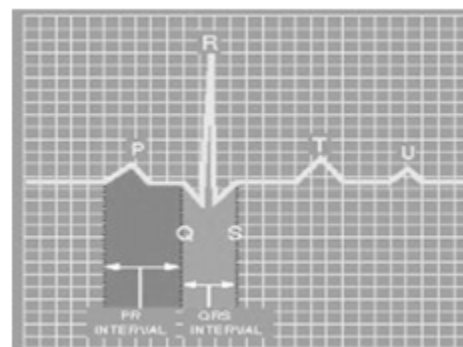
The QRS complex represents ventricular depolarization. The QRS complex consists of three waves: the Q wave, the R wave, and the S wave. It is measured from the beginning of the Q wave to the end of the S wave. Normal ventricular conduction and depolarization takes 0.11 seconds or less (Surawicz, 2009).

Normal Findings:

- All the QRS complexes have uniformity throughout (the same size, shape and direction).
 - All QRS complexes are of equal duration or width.
 - The R to R interval between each QRS is regular.

Abnormal Findings:

- The QRS complexes vary in shape, width and direction.
- The QRS complex is greater than 0.11 seconds wide.
- The R to R interval between each QRS is irregular.

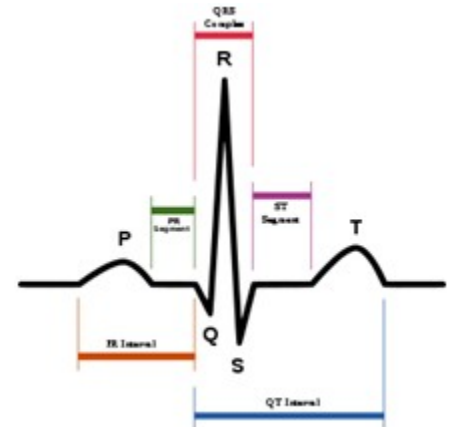


Step 5b - ST-T Wave

The ST segment and T wave represent ventricular repolarization. The cells are returning back to their polarized status and the heart is getting ready for yet another contraction.

Normal Findings:

- The ST segment should be electrically neutral (or near neutral) and should be sitting on the isoelectric baseline or no greater than 1 mm above or below the isoelectric line.
- The T wave is upright whenever the R wave is upright. The T wave deflects downward when the R wave is downward.



Abnormal Findings:

- There is greater than 1mm ST segment elevation or depression from the isoelectric line.
- The T wave is in the opposite direction of the R wave.

R on T Phenomenon

The term “**R on T phenomenon**” is used whenever an early ventricular beat lies near the vulnerable T wave.

The T wave is the most sensitive or vulnerable area in the cardiac electrical cycle. The heart is repolarizing and depending on where the premature beat intercepts the T wave determines the severity of the response.

If an early ventricular beat comes in on top of or near the T wave, the early beat could throw the heart into an uncontrollable repetitive pattern called ventricular tachycardia.

Step 6 - Rhythm Interpretation

After completing Step 5, make an educated decision on identifying the correct rhythm. Remember to correlate information from steps 1-5 along with your understanding of the heart’s anatomy, physiology, conduction pathways, and electrophysiology. Correlation between the rhythm and the normal function of the heart will make the decision to treat or not to treat make sense. Potential treatments take on a new interpretation when matched with pathophysiology.

Nursing Priorities and Potential Treatments

Interpreting the actual ECG rhythm is only part of your assessment. Using the rhythm along with your other assessment findings guides the care for your patient.

Current treatments for each type of ECG rhythm are presented, but keep in mind that the science of cardiology is changing quickly and your facility may have different standards.

Always follow current standards and your facility policies and procedures.

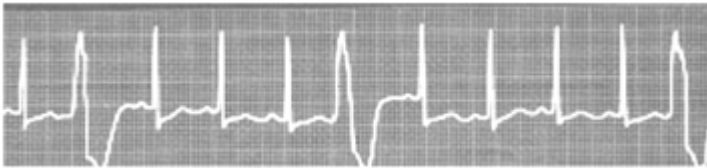Premature Ventricular Contractions

The heart was designed to conduct and contract from the atria to ventricle. When this mechanism is disrupted, the energy created by normal atrial function is diminished and the heart's efficiency is greatly reduced. Not all disruptions in normal ventricular rhythms are dangerous; however, each disruption should be evaluated and correlated with the patient's response.

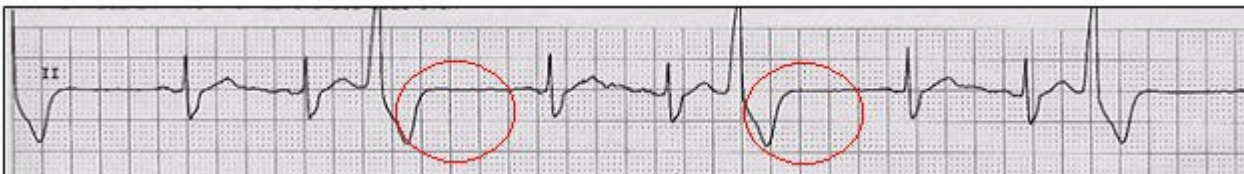
A premature ventricular contraction (PVC) is a depolarization that arises in the ventricles prior to the next expected sinus beat and is therefore labeled "premature." PVCs are also identified as unifocal or multifocal depending on the origination foci. Unifocal PVCs are similar in shape and arise from a single focus in the ventricle. Multifocal PVCs are different in size and shape and arise from different foci in the ventricle.

With PVCs the normal sequence of ventricular depolarization is altered. Instead of the two ventricles depolarizing simultaneously, a PVC causes the ventricles to depolarize at different times or sequentially; slowing conduction and often resulting in a wide and bizarre appearing QRS. Repolarization is altered; which may cause the ST segment and T wave to be in the opposite direction to the QRS complex.

Nursing Tip: The most important aspect of PVC recognition and treatment is "**does the PVC perfuse**". To determine PVC perfusion, listen to the apical heart rate with your stethoscope while palpating the radial pulse. Can you feel every beat you hear? Does every beat you feel have the same intensity? If not, the pulses that are absent or different are not perfusing normally. Knowing this will help ensure that the information you pass on is applicable to treatment decisions.



After the PVC, you may find a short pause before the next P wave. This is called a compensatory pause. The compensatory pause may or may not be present. Note the compensatory pause after each PVC.



Test Yourself

The short pause that occurs after a PVC and before the next P wave is called

a:

- A. FLB
- B. Ectopic
- C. Repolarizing
- D. **Compensatory pause**

Rationale: After the PVC, you may find a short pause before the next P wave. This is called a

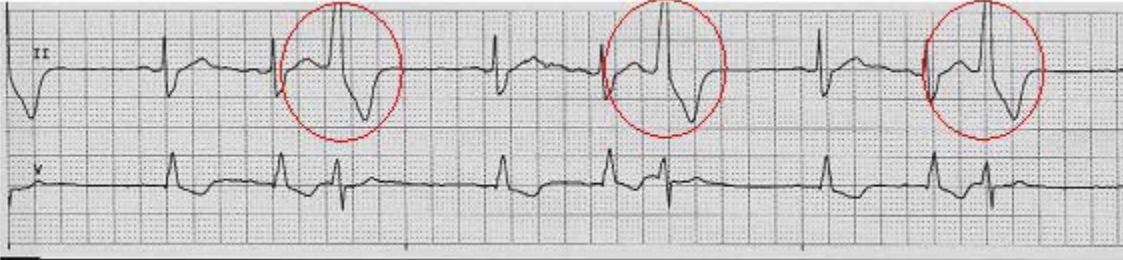compensatory pause. The compensatory pause may or may not be present

Unifocal PVCs

When a PVC originates from a single focus, its morphology or waveform characteristics look the same each time and it is called unifocal.

All PVCs from a unifocal source are identical in appearance.

The strip below shows Unifocal PVCs - note that the PVCs look the same.



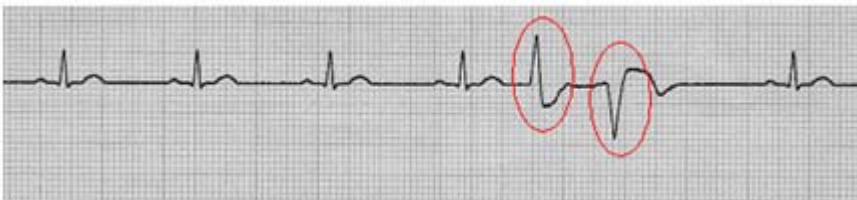Multifocal PVCs

When PVCs originate from a multiple foci, the morphology or waveform characteristics differ and originate from different, alternate pathways within the ventricles.

All PVCs from multiple foci are different in appearance.

Multifocal PVCs may occur in succession, as seen below or with normally conducted beats between them. They indicate a greater level of irritability in the myocardium.

The strip below shows Multifocal PVCs - note that the PVCs look different.



Test Yourself

Multifocal PVCs originate from _____ foci in the ventricles, while unifocal PVCs arise from the _____ focus.

Answer:

Different, Same

Rationale:

All PVCs from a unifocal source are identical in appearance.

All PVCs from multiple foci are different in appearance.

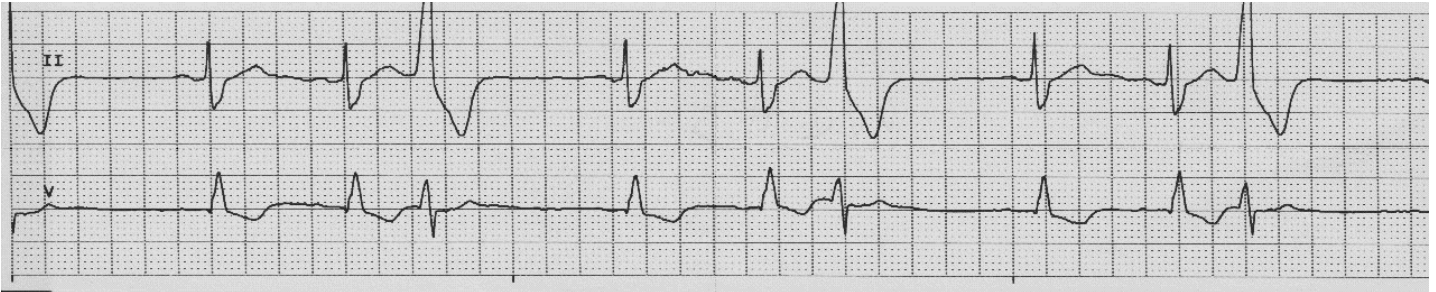
PVC Couplets and More

PVCs may also occur in succession. PVCs are called a **couplet** when there are 2 PVCs in succession, 3 or more PVCs in succession are termed **ventricular tachycardia**.

The term **ventricular bigeminy** is used for a grouped beating pattern when every other beat is a PVC (despite the underlying rhythm). For example, ventricular bigeminy is a when you see a pattern of one PVC, then one normal beat, then one PVC, followed by a normal beat.

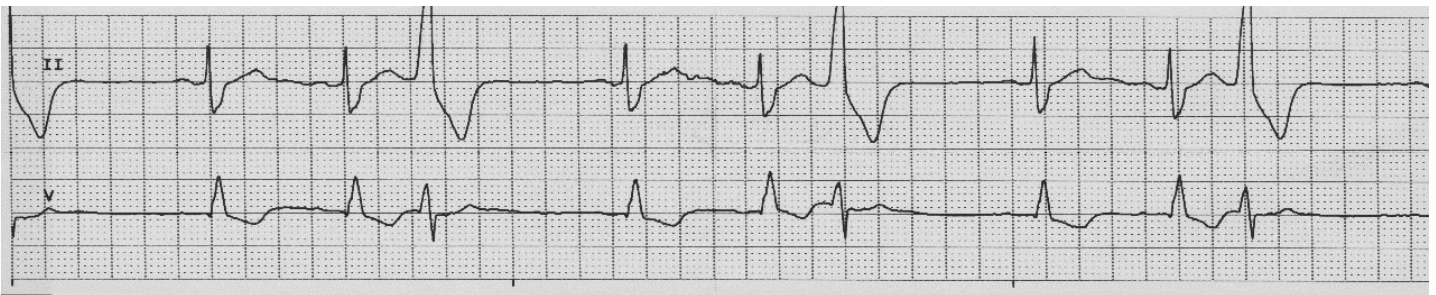If every third beat is a PVC, the term **ventricular trigeminy** is used; if every fourth beat is a PVC, **Ventricular quadrigeminy** is present; and so forth.

This strip is an example of **unifocal ventricular trigeminy** (every third beat is a PVC).



ECG Criteria for Premature Ventricular Contractions

1. **Heart Rate:** Depends on the underlying rhythm
2. **Rhythm:** The PVC beats are premature, so this will make the R to R interval irregular
3. **P waves:** There are no P waves associated with PVCs
4. **PR Interval:** There are no P waves associated with PVCs
5. **QRS Width:** greater than 0.11 seconds, wide and bizarre in appearance. T wave may be opposite direction of the QRS complex.
6. **Rhythm Interpretation:** Underlying rhythm with PVCs.



Self-Assessment:

Based on what you have learned so far; how would you interpret this strip?

1. Heart Rate: 75 beats per minute based on the small box calculation
2. Rhythm: Irregular R to R intervals due to ectopic beats which are premature, regular P to P interval in underlying rhythm; ectopic beats appear as every third beat
3. P waves: one before every normal appearing QRS, all look the same in an upright position

4. PR Interval: 0.16 when occurring before every normal appearing QRS
5. QRS Width: 0.08 when normal appearing QRS; 0.14 when ectopic; ectopic QRS are uniform in shape
6. Rhythm Interpretation: Normal sinus rhythm at a rate of 75 with trigeminal unifocal PVCs

Common Causes of PVCs

Identifying the cause(s) of PVCs is essential to determining whether a patient needs treatment. Treatment should focus first on the patient response or lack thereof to the PVCs. If the patient is symptomatic, immediate treatment should be instituted. For non-symptomatic patients with a definitive cause; treatment should focus on correcting the underlying issue.

Common causes of PVCs:

- Acute myocardial ischemia
- Acid/Base imbalances
- Digitalis toxicity
- Electrolyte imbalances
- Mechanical disturbances
- Other pharmacologic agents
- Hypoxemia
- Cardiomyopathy
- Hypothermia

Patients with a congenital heart abnormality are living well into adulthood. Additionally, many adult patients are being diagnosed with congenital abnormalities; and are undergoing surgical correction. Surgical procedures to correct these abnormalities may interrupt the conduction pathways. These interruptions may be due to cardiac tissue edema, surgical incising of the pathway and suture lines within the cardiac tissue among other issues. Conduction issues may present well after the surgical procedures, these conduction issues may require pacemaker insertion.

Test Yourself

True or False: Patients with renal problems may be at risk for developing PVCs due to an acid base imbalance.

True

Rationale: Common causes of PVCs include acute myocardial ischemia, acid/base imbalances, digitalis toxicity, electrolyte imbalances, mechanical disturbances, other pharmacologic agents, hypoxemia, cardiomyopathy, or hypothermia

Causes of PVCs - Acute Myocardial Ischemia

Acute myocardial ischemia is the most common cause of PVCs leading to lethal arrhythmias. When ischemic tissue loses its ability to control the movement of potassium and sodium across the cell membrane, ventricular arrhythmias, like ventricular tachycardia (VT) and ventricular fibrillation (VF), may occur.

Cardiac ischemia also has the potential to damage the electrical conduction system. In addition, due to the catecholamine release and electrolyte imbalances that may be present during cardiac ischemia, PVCs are a very dangerous sign, because they could lead to VT and VF (Marzlin & Webner, 2006).

Causes of PVCs - Electrolyte Imbalances

Electrolyte imbalances can cause any number of physiologic problems. However, there are a number of electrolytes that impact the heart, and consequently cardiac rhythms.

Potassium, calcium, and magnesium are three electrolytes most commonly associated with ventricular ectopy. If these electrolytes are not balanced they predispose the cell membranes of the myocardial tissue to instability. These imbalances may cause other ECG changes and symptoms.

Potassium Imbalances

Hypokalemia

Hypokalemia, a low potassium level, look for ST segment depression, flattened or inverted T waves or a small upright wave that follows the T wave, called a U wave.

Your patient may experience shallow respirations, a slow weak pulse, abdominal cramps, confusion, drowsiness, muscle weakness or tenderness, paralytic ileus, postural hypotension, increased urine output, and nausea and vomiting.

Non-symptomatic hypokalemia or a potassium level greater than 3.2 is usually treated with potassium supplements by mouth. Symptomatic hypokalemia manifested by ventricular ectopic beats, ventricular tachycardia, or ventricular fibrillation or a potassium level less than 3.0 requires immediate treatment with a potassium infusion and transfer to the intensive care unit for monitoring.

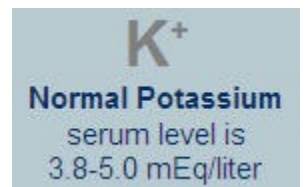
Hyperkalemia

Hyperkalemia, a high potassium level, causes tall, peaked T waves and shortened QT interval on the ECG. As the potassium level rises, there is a progressive lengthening of the PR interval and QRS duration and the P wave may completely disappear (Kee, Hayes & McCusition, 2009).

Your patient may experience irritability, anxiety, abdominal cramping, diarrhea, intestinal colic, weakness of the lower extremities, and paresthesia; abnormal sensations such as burning or prickling (Lewis, Dirksen, Heitkemper, Bucher & Camera, 2011).

Non-symptomatic hyperkalemia is often treated with a non-potassium sparing diuretic or kayexalate (a cation exchange resin that acts as a potassium-lowering agent).

Symptomatic hyperkalemia treatment includes intravenous calcium gluconate to stabilize the myocardium, intravenous sodium bicarbonate to correct the acidemia, or a glucose and insulin infusion to drive extracellular potassium back into cells (Kee et al., 2009).

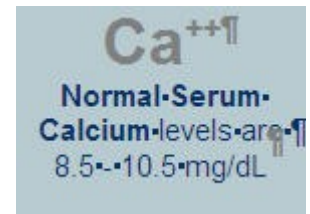


Hyperkalemia that manifests as bradycardia and asystole is a medical emergency and should be treated aggressively, often with hemodialysis along with infusions of calcium, sodium bicarbonate, and insulin and glucose. Management within the ICU is imperative.

calcium and Magnesium Imbalances

Hypocalcemia

Hypocalcemia causes a lengthening of the ST segment and the QT interval. Your patient may have numbness and tingling of the fingers, tingling around the mouth, hyperactive reflexes, abdominal and muscle cramps, tetany, laryngeal muscle spasms, bone fractures, vomiting, diarrhea, and seizures.



Hypocalcemia is treated with oral calcium supplements and intravenous calcium. Vitamin D supplements can be used in conjunction with the oral calcium.

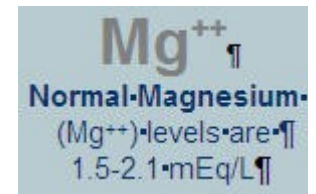
Hypercalcemia

Hypercalcemia is represented as shortened QT intervals and lengthened QRS complex. Your patient may have fatigue, muscle hypotonicity, drowsiness, disorientation, anorexia, nausea, vomiting, polyuria, itching, confusion, paresthesia, stupor, constipation, kidney stones, thirst, bone pain, and even coma.

Calcitonin or intravenous saline followed by a loop diuretic, such as Lasix, are often used to treat hypercalcemia. intravenous phosphate may also be used to decrease the serum calcium (Lee et al., 2009). It is recommended a patient drink as much as 3000 – 4000 mL of fluid daily to promote excretion of calcium (Lewis et al., 2011).

Hypomagnesemia

Hypomagnesemia is often represented as prolonged PR and QT intervals. The patient may experience hyperactive deep tendon reflexes, tremors, seizures, cardiac dysrhythmias, and confusion (Lewis et al., 2011).



Hypomagnesemia is treated with intravenous magnesium. Use caution when administering intravenous magnesium, rapid infusion may lead to hypotension, cardiac or respiratory arrest (Lewis et al., 2011).

Hypermagnesemia

As levels of serum magnesium increase, patient becomes lethargic, deep tendon reflexes are lost; and respiratory and cardiac arrest may occur. The treatments for high levels of serum magnesium are intravenous calcium chloride or calcium gluconate (Lewis et al., 2011).

Hypoxia

Hypoxia is insufficient oxygenation of the blood and can cause irritability of the myocardium as well as causing metabolic acidosis. Treatment is guided by determining the cause of the hypoxemia.

Besides PVCs, the hypoxic patient's ECG may show inverted T waves or ST elevation.

O₂
Normal PaO₂
value is
75-100 mm Hg

Causes of Hypoxemia

Pulmonary Edema	Coronary artery disease
Narcotics	Pneumonia
Sedation	Pulmonary embolism
Chronic obstructive pulmonary disease	

Metabolic Acidosis

Metabolic acidosis is excess serum hydrogen in the presence of low pH. Your patient may experience lethargy, drowsiness, headache, nausea, vomiting, diarrhea, and abdominal pain. Treatment will be aimed at increasing the pH. Intravenous sodium bicarbonate is the drug of choice. Intravenous fluids and oxygen may also be ordered.

Causes of metabolic acidosis include:

- Renal disease
- GI fistulas
- Diarrhea
- Impaired liver function
- Intestinal malabsorption
- Starvation
- Ingestion of acids or acid salts
- Ketosis
- Hypoxia

Hypothermia

A core temperature below normal is considered hypothermia. In the early stages the body responds to hypothermia by peripheral vasoconstriction and shivering, which produces heat (Lewis et al., 2011).

Severe hypothermia or a core body temperature below 30 degrees C or 86 degrees F causes all bodily processes to slow down. Besides PVCs, the ECG will then show a prolongation of the PR, QRS and the QT intervals. Profound bradycardia, ventricular fibrillation and asystole maybe be present (Lewis et al., 2011).

Severe hypothermia is a medical emergency.

Patients with severe hypothermia should be treated with warmed fluids and warming devices taking care not to increase the core temperature by more than

Cardiomyopathy

Cardiomyopathy is disease of the myocardium. The disease refers to the structural and functional aspects of the heart.

There are 3 types of cardiomyopathy:

- Dilated cardiomyopathy
- Hypertrophic cardiomyopathy
- Restrictive cardiomyopathy

In dilated cardiomyopathy, the heart enlarges and the ventricles become hypertrophied. This leads to a decrease in cardiac output, which predisposes the myocardium to arrhythmias.

In hypertrophic cardiomyopathy, the left ventricle becomes hypertrophied and hypercontractile.

In restrictive cardiomyopathy, the myocardium becomes thick and fibrotic. The heart's contraction is restricted.

Ventricular arrhythmias are more common in the first two types of cardiomyopathy.

Cardiomyopathy

Your patient with cardiomyopathy may experience shortness of breath, chest pain, edema, intolerance of activity, dizziness, and fatigue.

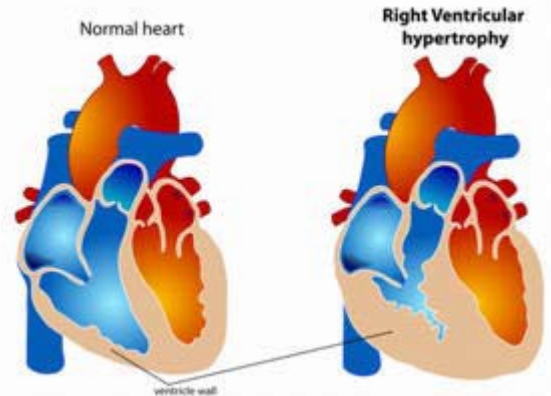
Treatment may include diuretics, beta-blockers, Ca⁺⁺ channel blockers, ACE inhibitors, anticoagulants, and antiarrhythmics. Oxygen therapy and fluid management will also be included. In some cases, cardiac transplant may be necessary. Internal cardiac defibrillators are common in this patient population.

In addition to PVCs, the ECG may reveal a widened QRS complex or prolonged PR interval.

Digitalis Toxicity

Digoxin is a cardiac glycoside used to treat congestive heart failure and atrial arrhythmias. Digoxin increases the force of contraction (positive inotrope), decreases the heart rate (negative chronotrope) and decreases the speed of AV node conduction (negative dromotrope) (Lee et al., 2009). Medications such as Xanax, quinidine, amiodarone, and calcium channel blockers increase the effects of digoxin. Use digoxin cautiously in patients who are on diuretics that deplete potassium, because hypokalemia potentiates digoxin toxicity (Garhart & Nazareno, 2011).

Digoxin toxicity is defined as a serum digoxin level equal or greater than 2.0 ng/mL (Gahart & Nazareno, 2011).



Digoxin
Normal dig level
is less than
2.1 ng/mL

With digoxin toxicity, the ECG shows a prolonged PR interval (Lewis et al., 2011). The patient may experience weakness, visual distortion, vomiting, dizziness, and confusion (Gahart & Nazareno, 2011).

Treatment includes stopping the digoxin, correcting electrolyte imbalances, evaluating the use of other prescribed drugs that may precipitate the effect of the digoxin, and in symptomatic bradycardia, providing temporary pacing of the heart. If the serum level is greater than 6 ng/mL, Digibind, an antidote for digitalis toxicity may be ordered (Gahart & Nazareno, 2011).

Vision Changes in Your Patient?

This may be a clue to Digoxin toxicity. Yellow vision or hazy vision may be noted. Listen to your patient and/or ask about vision changes. Include this information in patient teaching.

Pharmacologic Agents

Medications that are prescribed to treat arrhythmias may actually cause lethal arrhythmias. Quinidine, procainamide (Pronestyl), disopyramide (Norpace), sotalol (Betapace), amiodarone (Cordarone), and propafenone (Rythmol), are among these drugs. These drugs cause an increase in the QT interval, putting the patient at greater risk for PVCs.

Patients that are prescribed these medications should be placed on cardiac monitoring, and the QT interval measured every shift. If the QT interval increases by 25% from the baseline (established prior to administering the drug), the physician should be notified and the drug should be stopped.

Other non-cardiac drugs may increase the QT interval and put your patients at risk for lethal arrhythmias. It is advisable to consult a medication reference to determine which of your patient's current medications may predispose them to a prolonged QT interval.

Test Yourself

True or False: Antidysrhythmic drugs are prescribed to treat arrhythmias and pose no additional risk.

False

Rationale: Medications that are prescribed to treat arrhythmias may actually cause lethal arrhythmias. Drugs that cause an increase in the QT interval put the patient at greater risk for PVCs.

Mechanical Causes of PVCs

A physical irritation of the myocardium may cause PVCs. When a catheter, Swan-Ganz, central venous, peripherally inserted central catheter, or other centrally placed catheters are inserted, arrhythmias may occur. Most central venous catheters are placed just above the superior vena cava atrial junction. Exceptions to this rule are the Swan-Ganz catheter and cardiac catheterization catheters which are passed deeper into the heart.

Tips of the centrally placed catheter when placed into the ventricles may irritate the myocardium causing atrial or ventricular ectopic beats. The catheter should be repositioned immediately.

Cardiac surgery, especially for congenital defects or valve replacements may cause ectopic beats. The surgical incision in the myocardium may be enough to cause ectopic beats.

Replacing valves requires excising tissue and suturing which may disrupt the conduction pathways. Edema from the incision may cause a temporary disruption. Postoperative arrhythmias may require pacemaker support either temporarily or permanently.

Nursing Tip:

If your patient is not on a cardiac monitor, how do you assess for possible PVCs? Listen to the apical heart rate for one minute while palpating a radial pulse. Auscultation may reveal an irregular heart rhythm and palpation will indicate if the beat is perfusing. SUSPECT PVCs! Question whether your patient needs to be on a cardiac monitor or perhaps transferred to a telemetry unit!

Nursing Tip:**Check your patient! Do not treat the monitor!**

Have you ever seen what looked to be ventricular tachycardia on the monitor only to rush into the room to see the patient brushing his teeth or the respiratory therapist percussing the patient?

Assessing the Patient with PVCs

Assess your patient for:

- Changes in the mental status
- Check for pulse
 - Check for perfusion of beats
- Changes in the blood pressure
- Check O₂ saturation
- Changes in skin color, temperature, or decreased urine output.

Interventions

Interventions related to PVC treatment will vary depending on the underlying rhythm, frequency of ectopic beats and symptomology. The gold standard for arrhythmia treatment within the healthcare community is the American Heart Association (AHA) Advanced Cardiovascular Life Support guidelines. Additionally, the AHA has separate guidelines for the pediatric and neonatal populations.

Although your facility may utilize slightly different treatment modalities, in most cases a healthcare provider will order treatment if a patient experiences:

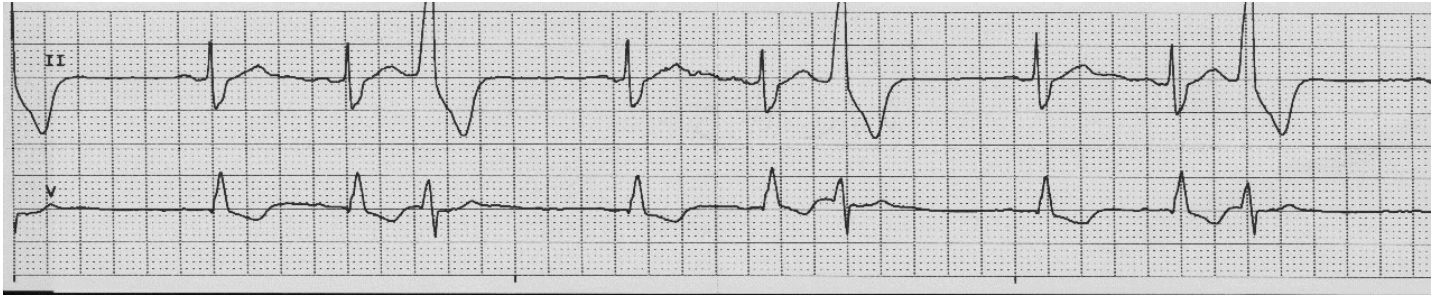
- Frequent PVCs (greater than 6/minute)
- Runs of consecutive PVCs (couplets, triplets)
- Multifocal PVCs
- "R on T" phenomenon
- PVC occurring in the setting of acute myocardial infarction
- Non-perfusing PVCs with underlying bradycardia

To assist healthcare professionals to safely care for patients that require cardiac monitoring, cardiac monitoring systems provide a variety of built-in alarm parameters. Parameters can be adjusted according to a patient's individual needs.

PVC Case Study

You are working in a cardiac step-down unit providing care for a 79-year-old gentleman admitted with atrial fibrillation. Your patient has an amiodarone drip infusing. The patient is also showing signs of congestive heart failure (CHF) and was started on 40 mg intravenous Lasix BID.

You note the patient has the following rhythm displayed across the screen:



What is your interpretation of this rhythm?

1. Heart Rate: 75 beats per minute based on the small box calculation
2. Rhythm: Irregular R to R intervals due to ectopic beats which are premature, regular P to P interval in underlying rhythm; ectopic beats appear as every third beat
3. P waves: One before every normal appearing QRS, all look the same in an upright position
4. PR Interval: 0.16 when occurring before every normal appearing QRS
5. QRS Width: 0.08 when normal appearing QRS; 0.14 when ectopic; ectopic QRS are uniform in shape
6. Rhythm Interpretation: Normal sinus rhythm at a rate of 75 with trigeminal unifocal PVCs

What else do you need to know about the patient?

1. What is the patient's mental status
2. Do the ectopic beats perfuse
3. What is the patient's blood pressure
4. Is this rhythm new to the patient

Critical Thinking:

What factors might cause this patient to experience PVC's?

Your assessment finds him asleep. His blood pressure and heart rate are within normal limits. His oxygen saturation is 98% on 2L via nasal cannula oxygen. You report that the patient is in trigeminy with perfusing pulses. Both you and the physician suspect an electrolyte imbalance. The physician orders serum electrolytes including K⁺ and Mg⁺⁺ levels to be drawn STAT.

Critical Thinking:

What are other possible causes for this rhythm besides an electrolyte imbalance?

Although an electrolyte imbalance is the likely cause, especially in a patient that has been recently started on Lasix, a non-potassium sparing loop diuretic; this patient has other risk factors for ventricular arrhythmias. The patient is on amiodarone, which has the potential to cause arrhythmias. He also has signs of CHF that might indicate a dilated ventricle, another possible cause of

arrhythmias.

Remember: PVCs are not a lethal arrhythmia but may progress to a lethal arrhythmia if not recognized and treated when appropriate.

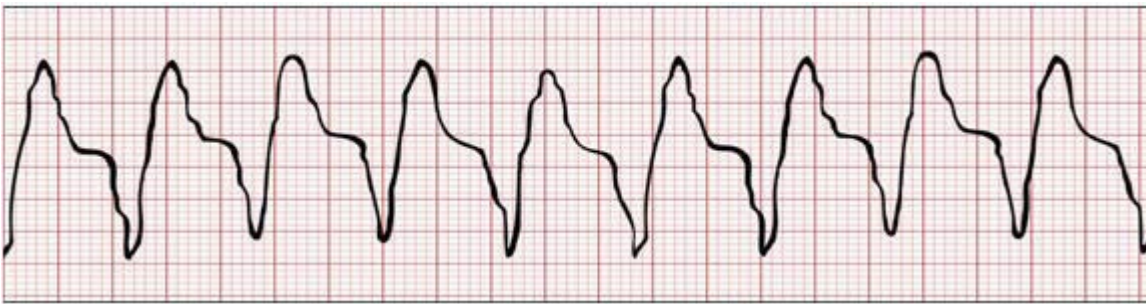Ventricular Tachycardia

Ventricular tachycardia (VT) is more conducive to being a lethal arrhythmia than PVCs. Ventricular tachycardia is a symptom of an irritated ventricular myocardial tissue.

Three or more consecutive PVCs characterize ventricular tachycardia. Irritable foci originating in the ventricles overtake the heart's normal pacemaker, SA node increasing the heart rate to between 100-250 beats/minute.

Since conduction does not follow the normal pathway it results in a widened QRS complex (greater than or equal to 0.11 sec). Normally the QRS complex is followed by a large T wave in the opposite deflection of the QRS complex.

Ventricular tachycardia can take on a few different shapes and sizes and the treatment may be different. Stop and take a closer look.



ECG Criteria for Ventricular Tachycardia

1. **Heart Rate:** 100-250 bpm.
2. **Rhythm:** Regular ventricular rhythm.
3. **P waves:** P waves not seen
4. **PR Interval:** Not applicable
5. **QRS Width:** greater than 0.11 seconds, wide and bizarre in appearance; it is difficult to differentiate between the QRS and the T wave, ST-T Waves are opposite deflection from QRS
6. **Rhythm Interpretation:** Ventricular tachycardia

Nursing Priorities:

- Assess your patient to determine if he or she is stable (asymptomatic) or unstable (symptomatic)
- Examine the patient for weak, thready, or no pulses; hypotension, altered mental status, chest pain and signs of shock
- Your patient should lie down to prevent further compromise and potential falls.

Pulseless VT is a medical emergency!

Cardiopulmonary Resuscitation should begin immediately!

Treatment is guided by the severity of the symptoms. Patients who have a pulse and a blood pressure to maintain sufficient cardiac output. However, a stable patient may change to an unstable patient rapidly with a sustained ventricular tachycardia.

Sustained vs. Unsustained VT

Monomorphic VT is regular and each QRS complex has a uniform appearance. Occasionally the first or the last beat may have a slightly different appearance.

Sustained VT is defined as VT lasting more than 30 seconds; unsustained VT lasts less than 30 seconds. VT requires intervention due to the potential for decreased cardiac output and the potential rhythm to change to ventricular fibrillation (Lewis et al., 2011).

Possible Causes:

- Myocardial irritability
- Acute MI
- Coronary artery disease (CAD)
- Drug toxicity
- Electrolyte imbalance
- Cardiomyopathy
- Idiopathic - of spontaneous and unknown origin
- Inappropriately placed devices
- R on T phenomenon

Test Yourself

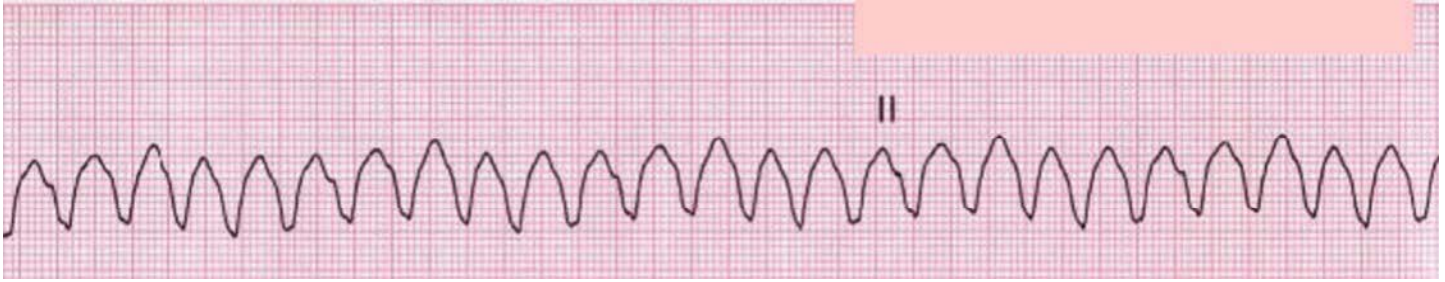
The most important factor in determining the treatment for a patient in VT is if the patient has a ____.

Pulse

Rationale: Treatment is guided by the severity of the symptoms. Patients who have a pulse and a blood pressure to maintain sufficient cardiac output. However, a stable patient may change to an unstable patient rapidly with a sustained ventricular tachycardia.

Case Study:

You are caring for a patient who overdosed on tricyclic medications. You are at the central monitoring station when you see this rhythm on the monitor.



What is your first intervention?

CHECK YOUR PATIENT or CALL A CODE

Check your patient

Rationale: This arrhythmia may be caused by brushing teeth or a respiratory treatment.

Now that you are in the room

- Assess your patient
 - CABs (Circulation, Airway, Breathing)
 - Does the patient have a pulse? Yes
 - Is the patient breathing? Yes
 - Is there any reason for this arrhythmia? No
 - Is the patient awake? Yes
 - Does the patient complain of chest pain or shortness of breath? No
- Check vital signs

Your patient is talking, oriented, has no complaints of chest pain or shortness of breath, and blood pressure is stable (greater than 90 systolic blood pressure). You determine that your patient is stable.

Now, what rhythm is your patient in?

1. **Heart Rate:** 200 bpm.
2. **Rhythm:** Regular ventricular rhythm.
3. **P waves:** P waves not seen
4. **PR Interval:** Not applicable
5. **QRS Width:** 0.28 seconds, wide and bizarre in appearance; it is difficult to differentiate between the QRS and the T wave
6. **Rhythm Interpretation:** Ventricular tachycardia, with a pulse

Stable ventricular tachycardia with a pulse.

Critical Thinking:

Your patient has a pulse, is awake and alert, and is not complaining of any symptoms other than a fast heart rate. What is your next intervention?

You know that this patient may decompensate at any time due to the hemodynamic changes that are

occurring in the heart. His normal heart rate is 70 and now his heart rate is 200, what does this change in heart rate have the potential to do to his cardiac output?

You know that the formula for determining CO is heart rate X stroke volume. You also recognize that a tachycardic rhythm of any type will reduce the filling time of the ventricles thus decreasing the stroke volume. The increased heart rate and decreased stroke volume correlate to decreased CO.

Your patient is compensating now, but for how long? Treatment to convert this rhythm back to his baseline is imperative.

Treatment of Ventricular Tachycardia with a Pulse

The American Heart Association (AHA) has developed the gold standard for treating dysrhythmias including specific algorithms for treatment of rhythms such as ventricular tachycardia. Ventricular tachycardia with a pulse follows the tachycardia (with pulse) algorithm. The information contained within the treatment portion of the course reflects these standards.

Nursing interventions include:

- Maintain patent airway
- Administer oxygen
- Place cardiac monitor on patient if not already on a monitor
- Obtain the emergency crash cart
- Ensure intravenous access
- Obtain a 12 lead ECG
- Stay with the patient; continue monitoring
- Page physician

When a patient has VT with a pulse, the physician may want to try an antidysrhythmic medication such as amiodarone. Antiarrhythmic drugs are given as a loading dose followed by intravenous infusions. Once the arrhythmia has converted, the physician may choose to place the patient on an oral preparation to maintain control.

If the medication is unsuccessful in converting the patient back to their baseline or stable rhythm, cardioversion may be indicated. Cardioversion is indicated if the patient has a pulse, but is showing signs of decompensation, hypotension or change in mental status. If the patient is awake, consider sedating the patient while you are obtaining the defibrillator. Cardioversion is accomplished using a synchronized mode and decreased joules. Cardioversion should be attempted as soon as possible (AHA, 2011).

Synchronized Electrical Cardioversion

Cardioversion delivers an electrical energy just after the “R” wave of the QRS complex. The exact procedures, number of joules, placement of electrodes and pads will depend on the type and brand of defibrillator used at your facility.

Follow your facility and device specific guidelines for cardioversion keeping in mind that the device must be synchronized to the “R” wave in order to cardiovert the patient successfully.

If the patient is defibrillated instead of cardioverted, the patient may go into ventricular fibrillation. Ventricular fibrillation is caused when the electric current falls on the refractory period of the cardiac electrical cycle.

For cases of monomorphic VT, the AHA recommends delivering the following biphasic synchronized shocks: narrow regular: 50-100 J; narrow irregular 120-200J; wide regular 100J. (AHA, 2011). The recommendations may differ depending on the device used at your facility.

When a defibrillator is in "synch" mode, you should easily observe the synchronizing spike on the display after you place the defibrillator paddles or pads on the patient's chest. These prevent the defibrillator from discharging during the vulnerable T wave period of a cardiac cycle in "synch" mode.

If hypokalemia or hypomagnesemia are suspected as the cause of VT, the imbalance can be treated concurrently with cardioversion. If the cardioversion is unsuccessful, it is possible that patient's condition might deteriorate into a pulseless arrest rhythm such as ventricular fibrillation (VF) or asystole. These conditions will be discussed later in this course.

Ventricular Tachycardia without a Pulse is an EMERGENCY

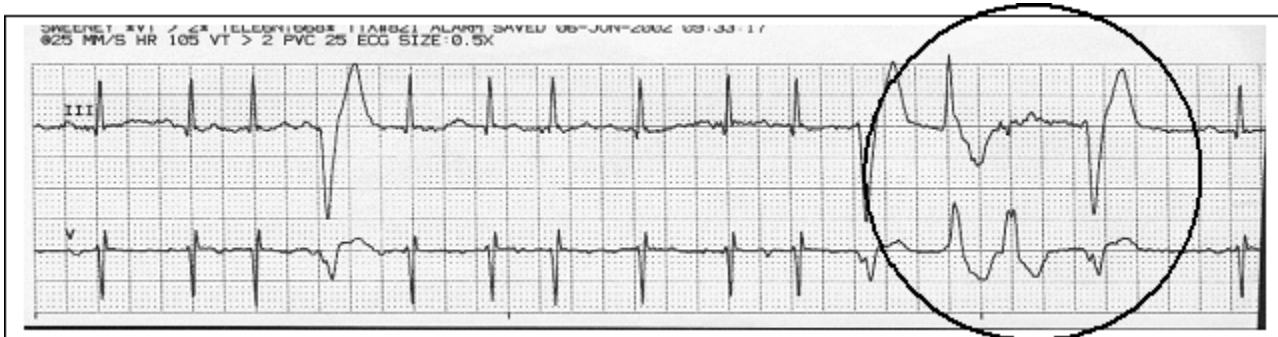
Following the AHA, Advanced Cardiac Life Support Algorithms for tachycardia without a pulse, you must begin CPR and defibrillate as soon as possible.

Nursing interventions for VT without a pulse include the following:

- Call for help
- Start CPR
 - Administer oxygen, if available
 - Attach defibrillator pads
 - Determine if rhythm is shockable
- If you have the AHA ACLS training and are competency validated in rhythm recognition shock the patient immediately
- If you are not AHA ACLS trained and are not competency validated in rhythm recognition, use the Automatic External Defibrillator (AED) option on the defibrillator
- If there is not an AED option on the defibrillator, continue CPR until help arrives
- Continue CPR for two minutes between shocks
 - Ensure vascular access

Polymorphic Ventricular Tachycardia

Polymorphic VT is defined as VT arising from more than one irritable foci within the ventricular myocardium. Note that the PVCs below do not look uniform in appearance. The different appearance of the three PVCs circled below is an example of polymorphic VT. The QRS complexes are wide with varying shapes.



ECG Criteria for Polymorphic Ventricular Tachycardia

1. **Heart Rate:** 100-250 bpm
2. **Rhythm:** Irregular
3. **P waves:** May or may not be seen.
4. **PR Interval:** Not applicable
5. **QRS Width:** greater than 0.10, wide and bizarre, differ one from another. ST-T Waves: differ with every beat, may or may not be seen
6. **Rhythm Interpretation:** Polymorphic ventricular tachycardia

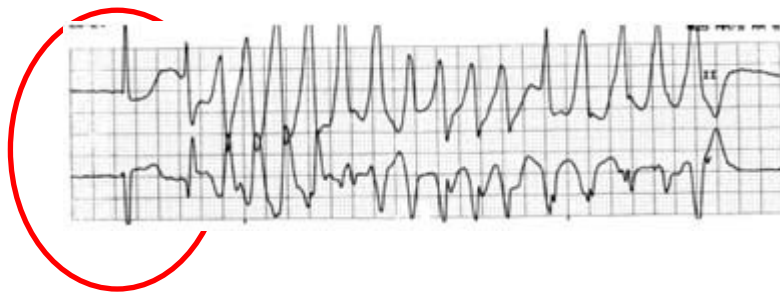
In most cases, polymorphic VT is treated according to the tachycardia with a pulse algorithm from AHA. Polymorphic VT without a prolonged QT interval is treated with antiarrhythmic drugs and/or cardioversion (AHA, 2011).

Polymorphic VT with a wide QRS complex should be treated as an emergency and defibrillated as soon as possible. (AHA, 2011).

Torsade de Pointes

Torsade de Pointes is a specific type of polymorphic ventricular tachycardia associated with a prolonged QT interval. This lethal rhythm is commonly called **torsades**. Torsades de pointes is French for "twisting of the points."

The QRS complexes in torsades appear to twist in a spiral around the baseline. The rhythm is precipitated by a prolonged QT interval. In the strip shown below, the sinus beat preceding the torsade de pointes has a QT interval of greater than 0.50 seconds.



A PVC that falls on the prolonged T wave can irritate the heart and put it into torsades. You will see a short pause and then the QRS complexes will peak up then down. The rate is normally very rapid (200 - 250 beat/min.).

The rhythm is usually poorly tolerated and leads to extremely diminished cardiac output. Seizures and syncope are common. If not stopped quickly, this rhythm can be lethal.

Torsades can result from drug toxicity or a reaction to antiarrhythmic medications such as procainamide, quinidine, or other drugs that prolong the QT interval. Bradycardia, hypokalemia, or hypomagnesemia can also cause torsades.

Test Yourself

True or False:

Torsades de pointes is a type of ventricular tachycardia that does not have a prolonged QT Interval.

False

Rationale:

The rhythm is precipitated by a prolonged QT interval.

ECG Criteria for Torsade de Pointes

1. **Heart Rate:** 200-250 bpm.
2. **Rhythm:** Irregular.
3. **P waves:** Not seen.
4. **PR Interval:** Not applicable.
5. **QRS Width:** greater than 0.11, QRS complexes are wide and bizarre, differing in size and deflection.
6. **Rhythm Interpretation:** Torsade de pointes.

Possible Causes

- Medications that prolong the QT interval: ex. quinidine, procainamide, disopyramide, sotalol, amiodarone, propafenone and dofetilide.
 - Electrolyte imbalances.
 - Severe bradyarrhythmias.
 - Liquid protein diets.
 - Mitral valve prolapse.
 - Central nervous system lesions.

Prevention and Treatment of Torsade de Pointes

Monitor the QT interval when your patient is taking one of the medications that might cause a prolonged QT interval. If the QT interval reaches 0.56 - 0.60 sec, notify the physician. Anticipate that the drug will be stopped, changed, or the dose reduced; or both.

Treatment of Torsades De Pointes

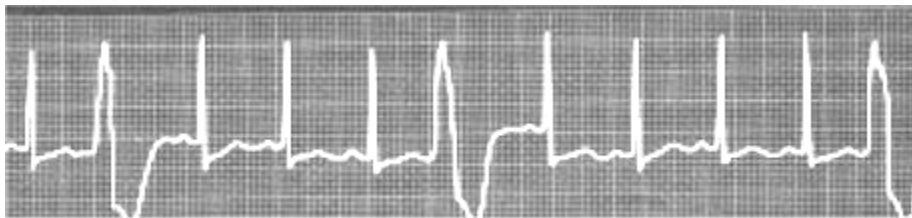- **Magnesium is the drug of choice** for torsades de pointes. Magnesium chloride or magnesium sulfate may be given intravenous push followed by an infusion
 - Override ventricular pacing may be attempted (AHA, 2011)

Ventricular Tachycardia Case Study

Mr. Smith is a 74 year-old man admitted to the hospital with complaints of chest pain and shortness of breath. He was given aspirin 325 mg orally in the ED upon admission and started on a nitroglycerin drip at 25 micrograms/minute.

His admitting diagnosis is rule out myocardial infarction and he was admitted to the telemetry unit. You obtain an initial set of vital signs: BP 118/58, pulse 90 irregular, respiration rate 22, O₂ saturation 94% on 4L O₂ NC.

He states he is no longer experiencing chest pain but has a headache. You place Mr. Smith on a telemetry monitor. You hand him the call bell and assure him you will be back shortly with Tylenol. You walk out to the desk and glance at the bank of telemetry monitors. You are not surprised to see this rhythm for Mr. Smith.



What is the interpretation of the strip?

1. **Heart Rate:** 110 beats per minute
2. **Rhythm:** Regular underlying rhythm with premature ectopic beats
3. **P waves:** One before every QRS in underlying rhythm
4. **PR Interval:** 0.12
5. **QRS Width:** 0.2 underlying rhythm; 0.16 ectopic beats
6. **Rhythm Interpretation:** Sinus tachycardia with multiple unifocal PVCs

What else would you like to know?

Mr. Smith's Medical History:

- **Past medical history:** Previous inferior wall MI two years ago with percutaneous transluminal coronary angioplasty (PTCA) to the right coronary artery, hypertension, and congestive heart failure.
- **Past surgical history:** Right total hip replacement four years ago.
- **Current medications:**
 - Aspirin 325 mg PO daily
 - KCL 20 mEq PO daily
 - Atenolol 25 mg PO BID

- Digoxin 0.125mg PO daily
- Zestril 5 mg PO daily
- Lasix 40 mg PO daily
- Extra Strength Tylenol 1000mg PO q4-6 hrs PRN for pain

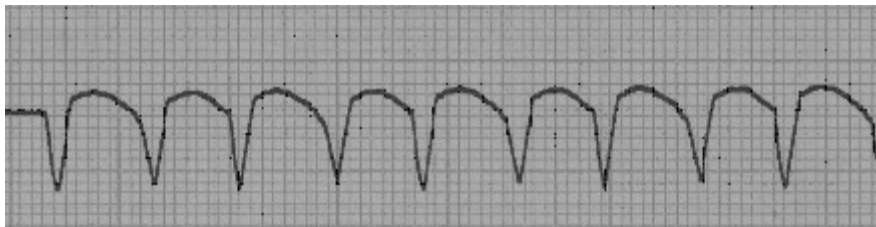
Admission Labs:

- WBC 6.7 Hgb 10.8 Hct 30.7
- Plt 186
- CPK 509 CKMB 34.1
- Troponin 2.6
- Na+137 K+ 3.5
- Ca++ 7.9 Mg++ 1.6
- Creat 1.0 BUN 24

Admission ECG: Sinus tachycardia with frequent PVCs, Q waves present in leads II, III, and avF.

You are standing at the med cart when you hear a nurse call for help. You turn to see the nurse standing in the doorway of Mr. Smith's room. The nurse tells you Mr. Smith is difficult to rouse. You grab the emergency crash cart and head for the room.

After connecting the telemetry leads to the defibrillator monitor, you see this rhythm.



Mr. Smith's blood pressure is 86/40. He has a faint, palpable pulse. The rate is difficult to count, but is approximately 160. He is diaphoretic and his respiration rate is 32. His O₂ Sat is 86% on 4L O₂ nasal cannula.

You grab the 100% non-rebreather mask from the crash cart and place him on 10L O₂. Another nurse calls a code, you ask her to stay at the head of the bed and monitor his airway. The secretary pages the physician for you.

Critical Thinking:

- What rhythm do you think you are seeing?
- How can you verify your initial thoughts?
- How does your patient assessment fit in with your initial interpretation, or does it make you think there may be another option?
 - What might have caused this condition?
 - What are your treatment options?

You think about the steps required for rhythm interpretation:

1. Rate
2. Regularity
3. P-wave Examination
4. P to R interval
5. QRS width
6. Rhythm interpretation

Your patient has a fast regular rhythm with QRS complexes that are wider than 0.12 seconds. Your initial interpretation is ventricular tachycardia. The complexes all look the same, so you further define the rhythm as monomorphic VT with a QRS greater than 0.12 seconds.

His labs show that his potassium and calcium are low and his magnesium is borderline low.

In addition, Mr. Smith has a history of coronary artery disease and his hospital course is consistent with acute myocardial ischemia.

You feel for your patients pulse and he is pulseless; his vital signs have deteriorated, you determine that the VT is unstable.

**VT without a pulse is a medical emergency
You begin CPR**

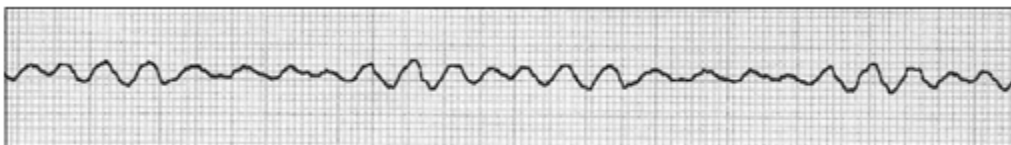
What should you do next? Prepare for defibrillation!

The physician arrives and orders the nitroglycerin drip to be shut off since it can cause hypotension. He orders an intravenous of 0.9% NS to facilitate medication administration and increase fluid volume if needed.

You placed the defibrillator pads on the patient's chest. The physician grabs the defibrillator paddles, places them on the patient's chest and asks you to charge the defibrillator to 120 joules.

"I'm going to shock on 3. One, I'm clear. Two, you're clear." (You make sure you aren't touching the bed or any equipment attached to the bed.) "Three, we're all clear." The physician discharges the paddles.

You now see this rhythm.

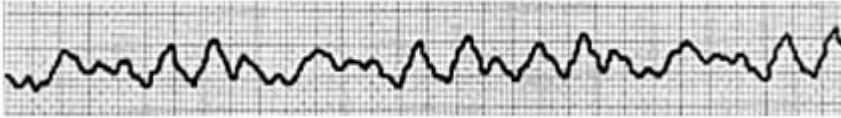


What happened? What is this rhythm?

Ventricular Fibrillation

Ventricular fibrillation (VF) is the result of chaotic electrical activity in the ventricles from either repetitive small areas of re-entry or from a series of rapid discharges from various irritable foci within the ventricle. This chaos causes the ventricles to quiver.

Scientists who have visualized the ventricular myocardium during VF describe it as "a can of worms." When the ventricles quiver, there is no cardiac output. You will not be able to hear any audible heart tones. There will be no palpable pulse. There will be no blood pressure. The patient will show signs of hypoxia and will become cyanotic. Apnea occurs.



ECG Criteria for Ventricular Fibrillation

1. **Heart Rate:** Not able to be determined
2. **Rhythm:** Irregular
3. **P waves:** Not seen
4. **PR Interval:** None
5. **QRS Width:** Cannot determine
6. **Rhythm Interpretation:** Ventricular fibrillation

Always assess the patient, not the monitor!

When the ECG electrodes are dry or accidentally knocked off the monitor may display interference that mimics V-fib.

Coarse and Fine Ventricular Fibrillation

Coarse VF

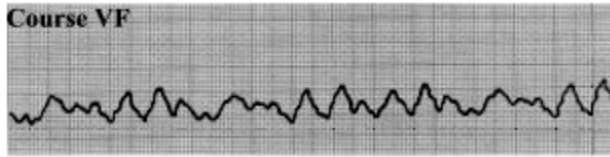
These terms are sometimes used to describe the size or amplitude of the waveforms in VF. Coarse VF is large, erratic undulations around the baseline. It often indicates a new onset of VF that will tend to be more easily defibrillated.

Fine VF

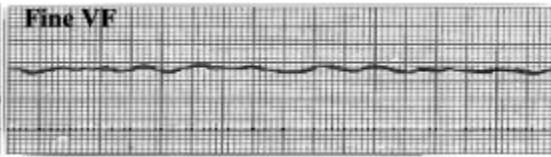
Fine VF appears as gentle undulations around the baseline. It resembles a tremor. Fine VF can indicate that the patient has been in VF for some time.

Medications are used to try to change fine VF into coarse VF, making the rhythm more sensitive to defibrillation.

Epinephrine and/or vasopressin are generally the drugs of choice for VF.



Coarse VF usually indicates the recent onset of VF, which can be readily corrected by prompt defibrillation.



The presence of fine VF that approaches asystole often means there has been a considerable delay since collapse, and successful resuscitation is more difficult.

Possible Causes of VF:

- Acute MI
- Untreated Ventricular Tachycardia
- Cardiomyopathy
- CAD
- Acid base imbalance
- Electrolyte imbalances

Treatment of Ventricular Fibrillation

Nursing Priorities:

Remember: You only have 3-5 minutes before brain damage or death occurs!

- Call for help
- Perform CPR
 - Defibrillate as soon as possible!
 - Resume CPR immediately after the shock and while the defibrillator is charging.

Sudden death from cardiac causes, often due to ventricular fibrillation, prompts at least 295,000 incidents of out of hospital emergencies (Heart.org, 2011).

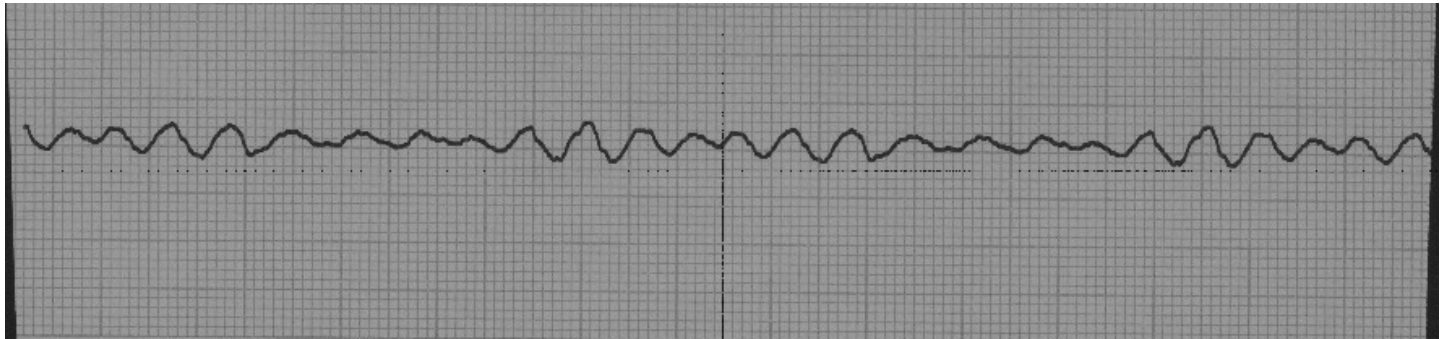
“DON’T WAIT, DEFIBRILLATE; perform CPR and PUSH HARD and FAST!”

Early defibrillation and hard and fast CPR are key components for survival for a patient in ventricular fibrillation.

Ventricular Fibrillation Case Study

Let's return to Mr. Smith.

As the code team continues to do CPR you determine that the rhythm on the monitor is VF.



You charge the defibrillator at 360J (monophasic), or (120-200J biphasic) and immediately deliver one shock after ascertaining that no one is touching the patient.

The code team resumes CPR for two minutes; while other members of the team attempt to gain vascular access and prepare epinephrine or vasopressin for administration. After two minutes check for a pulse and verify the patient still has a shockable rhythm. Give one shock at the same level as the first and immediately resume CPR. In addition, ensure that airway management, respirations, and chest compressions are effective.

Vasopressor medications such as epinephrine or vasopressin can be administered before or after the shock (AHA, 2011). As soon as vascular access is obtained and without interrupting CPR, vasopressin 40 units intravenously or epinephrine 1:10,000 1 mg intravenously is given every 3-5 minutes. Vasopressin is given as a one-time dose to replace either the first or second dose of epinephrine.

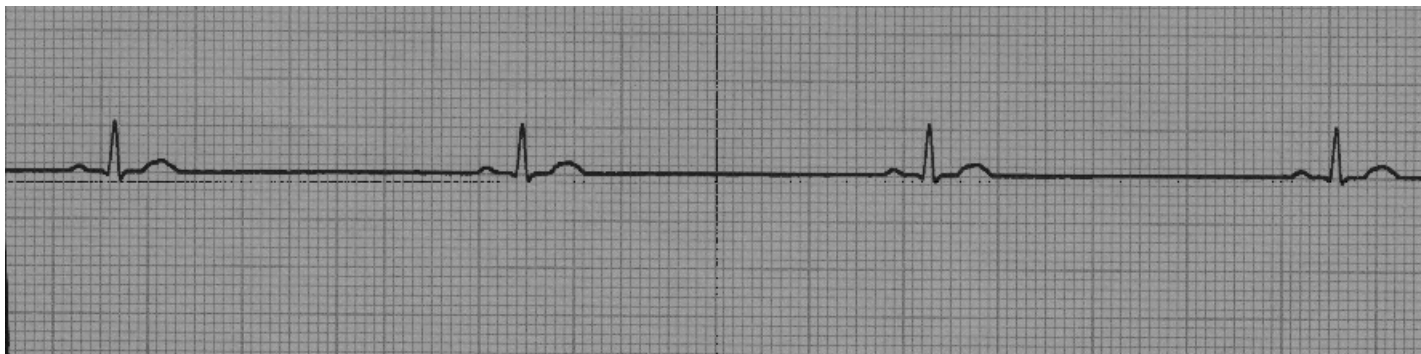
If VF still persists, consider an antiarrhythmic medication. Amiodarone 300 mg intravenous loading dose is the drug of choice and followed by an additional one time dose of 150 mg intravenous. A continuous infusion may be considered. Lidocaine may also be used. After two minutes of CPR have been completed, determine if the rhythm is shockable and proceed according to ACLS cardiac arrest algorithm (AHA, 2011).

Note: If unable to obtain intravenous access within 90 seconds, an interosseous device should be deployed. All code medications, including crystalloids and colloids may be given through the interosseous device.

Ventricular Fibrillation Case Study

Mr. Smith's rhythm converts to the one seen below.

Is there a pulse? Yes



1. **Heart Rate:** 40 bpm
2. **Rhythm:** Regular
3. **P waves:** Prior to every QRS
4. **PR Interval:** 0.16
5. **QRS Width:** 0.02
6. **Rhythm Interpretation:** Sinus Bradycardia

His blood pressure is 70/36. Since his heart rate and blood pressure are low (he is symptomatic), the physician orders Atropine 0.5 mg intravenous. After receiving the medication Mr. Smith's heart rate increases to 60 bpm and his BP is now 90/50.

Mr. Smith's airway is being managed effectively by endotracheal intubation performed during the code. Arterial blood gases and lab work has been drawn. You transport your patient to the intensive care unit.

Remember:

**As soon as VF is detected
perform CPR and defibrillate as soon as possible!**

Long Term Treatment Options for Ventricular Arrhythmias

Electrophysiology Study (EPS)

EPS is defined as a simple, non-invasive non-surgical evaluation of the electrical conduction of the heart. A catheter is inserted into the right side of the heart in the cardiac catheterization laboratory that allows the electrophysiologist to determine the specific location of an arrhythmia. The goal is to find the irritable focus (foci). Radiofrequency ablation may be used to destroy the source of the arrhythmia. In most cases, medications may be discontinued.

Radiofrequency Ablation (RFA)

RFA is a nonsurgical procedure used to treat arrhythmias during an EPS study. A catheter with an electrode tip is introduced by fluoroscopy to the area of the heart muscle where the accessory pathway is located. A mild, painless radio frequency energy similar to microwave heat is transmitted to the pathway destroying the selected heart muscle cells.

If the irritable focus is not found, an **Automatic Implantable Cardioverter Defibrillator (AICD or ICD)** might be placed.

Automatic Implantable Cardioverter Defibrillators (AICD)

An AICD is a small programmable device that is surgically placed in the chest or abdomen. This device will deliver shocks to the heart when arrhythmias occur. AICD placement takes place in the cardiac cath lab or the OR. A small generator is placed in a pocket of muscle under the skin.

Sensing and defibrillation leads are attached to the generator and threaded into the heart or the tissue surrounding the heart. The leads can sense an arrhythmia, send the information to the generator, and if needed, the generator can send an electric current (small amount of joules) through the leads to defibrillate the heart.

The physician programs the AICD with a set number of joules and the number of beats of VT or seconds of VF to allow before defibrillation will occur, for example 26 beats of VT; defibrillate with 6 joules.

Since the current does not have to pass through skin, muscle, or bone before reaching the myocardium, small amount of joules can be used. The patient will still detect the shock but often remains conscious. Patients that receive an AICD will likely be prescribed antiarrhythmic drugs as well with the goal of preventing or quickly correcting a second lethal arrhythmia.

Defibrillator Differences

There are three different types of external defibrillators available:

- Monophasic
- Biphasic
- Automatic External Defibrillator

General discussion of these types of defibrillators follows, but keep in mind that you should follow the guidelines for whatever type or brand of defibrillator used at your facility.

Monophasic Defibrillator

Current flows in one direction from one paddle/pad to the other.

Biphasic Defibrillator

Electrical current flows in one direction during the first phase and reverses direction in the second phase thus passing through the heart twice. They are able to utilize fewer joules and cause less myocardial damage with equal or better results than monophasic defibrillators.

Automated External Defibrillator (AED)

An AED is a biphasic defibrillator that uses a “hands off” approach. The operator does not have to interpret the patient’s heart rhythm: the defibrillator does this for you. The defibrillator will also choose the appropriate action needed for that particular rhythm.

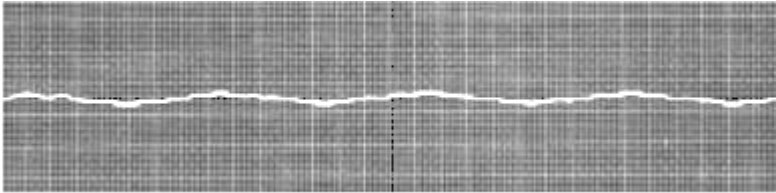
The AED consists of a small portable unit with a set of defibrillation electrode pads. When energized, a computer generated voice will prompt the operator what to do next. There are verbal and written directions for proper pad placement. Once the pads are placed, the AED will read and interpret the patient’s rhythm. The voice will prompt you to “shock” the patient, if needed. The operator needs only to push the “shock” button and stand clear. The AED determines the joules.

The AED does not have adjustable settings; however, some models can be switched to be used with a child, other models require special pads for the pediatric population. Besides the defibrillation electrode pads, the features on an AED consist of an “on/off” button, monitor screen, and a “shock” button. AEDs are often placed in “crowded” areas all across the world such as airports, stadiums, shopping malls, and airplanes. The goal of AEDs is to reduce the amount of time between when the patient goes into VF and the time of defibrillation.

Asystole

Asystole is the absence of any electrical activity. On the monitor it is seen as a flat or slightly wavy line. Clinically, your patient will be unconscious, apneic and pulseless.

Without a cardiac monitor you cannot differentiate between asystole and VF. Both rhythms require hard and fast CPR, however, the treatment is very different and the prognosis for resuscitation from asystole is less than VF since there is no electrical activity. In asystole, it is always important to verify this rhythm in two leads since a flat line could be the result of faulty leads or poor lead placement.



Test Yourself

If a patient's cardiac monitor indicates asystole, it's important to check the rhythm in ___ leads.

Answer:

Two

ECG Criteria for Asystole

1. **Heart Rate:** None
2. **Rhythm:** None
3. **P waves:** None
4. **PR Interval:** None
5. **QRS Width:** None; ST-T Wave: None
6. **Rhythm Interpretation:** Asystole

Possible Causes

- Severe metabolic deficit
- Acute respiratory failure
- Extensive myocardial damage or ruptured ventricular aneurysm

Just as interference can look like VF, lead displacement can look like asystole. Check your patient. If your patient is still talking to you, look for the leads that might have fallen off and replace them. Never substitute a monitor reading for a physical assessment.

Nursing Priorities

- **Assess your patient (CABs)**
- **Check rhythm in a second lead**
- **If your patient does not have a pulse, call for help**
- **Initiate CPR**

If your patient has a pulse, they are NOT in asystole.

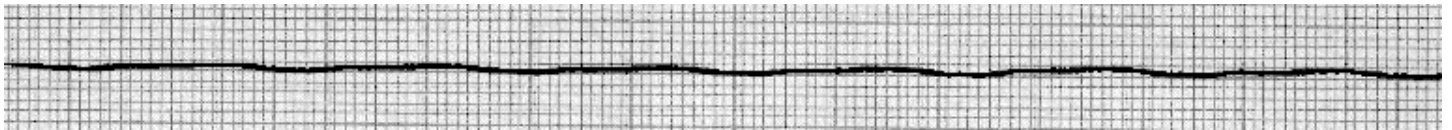
Asystole Case Study

Mrs. Wilson is a 90-year-old woman admitted with sepsis. She is on 100% non-rebreather mask with an O₂ saturation of 94%. Her respiratory rate is 30, HR 56, BP 96/50, rectal temp 96.0 degrees F. She is lethargic and disoriented to place and time.

Mrs. Wilson has a past history of chronic renal failure, diabetes mellitus and peripheral vascular disease. She is scheduled for dialysis later today. Blood cultures are pending. A urinalysis with culture & sensitivity was sent. A chest X-ray showed bilateral pleural effusions. You are in the middle of shift change and are giving report on this patient when . . .

The telemetry technician on your unit shouts your name and tells you go to into room 344 (Mrs. Wilson's room).

The monitor above her bed shows...



STOP! Assess the patient and check your monitor leads. She may have just pulled a lead off.

When you check for a pulse, there is none. Mrs. Wilson is cool to touch and is not arousable.

You shout for help and call a code. You immediately start CPR and attach the monitor when it arrives. A check in a second lead confirms asystole. What will you do next? Do you want to prepare for defibrillation? **No!**

Defibrillation is not appropriate unless there is some type of rhythm. Defibrillation actually stops the electrical activity. This allows for the heart's own pacemaker (SA node) to take over.

Treatment of Asystole

Treatment of asystole is CPR and intravenous medications. The goal is to "irritate" the heart into some kind of rhythm that then can be shocked.

Epinephrine or vasopressin should be administered.

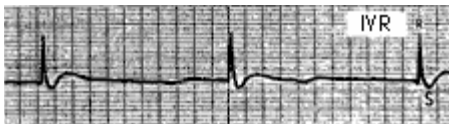Pulseless Electrical Activity

Pulseless Electrical Activity (PEA) is a cardiac rhythm where there is electrical activity but no mechanical response and therefore no cardiac output. Without cardiac output there is no pulse or blood pressure.

Several rhythms fit into this category including electromechanical dissociation (EMD), pseudo EMD, idioventricular rhythms, ventricular escape rhythms, post defibrillation idioventricular rhythms, and bradysystole rhythms.

The patient will be unconscious, apneic, and pulseless.

The most common cause of PEA is hypovolemia. The ECG criteria are variable, depending on the underlying rhythm.



Nursing Priorities

Assess your patient. Check for a pulse!

Check airway, breathing and circulation.

Through your assessment you may determine the cause of PEA.

Treat the cause!

Treatment of PEA

The treatment of PEA depends on the cause, so determining the cause is critical. While identifying the causes, CPR and epinephrine are appropriate treatments.

Common causes of PEA include:

- Hypovolemia
- Tamponade, cardiac
- Hypoxia
- Tension pneumothorax
- Hypothermia
- Toxins Hyper-/hypokalemia
- Thrombosis, coronary (acute, massive MI)
- Hydrogen ion – acidosis
- Thrombosis, pulmonary embolism

Test Yourself

True or False:

Your patient is unresponsive but the cardiac monitor shows normal sinus rhythm. Based on the cardiac rhythm, your patient will have a pulse.


False

Rationale: Pulseless Electrical Activity (PEA) is a cardiac rhythm where there is electrical activity but no mechanical response and therefore no cardiac output. Without cardiac output there is no pulse or blood pressure.

Agonal Rhythm

Agonal Rhythm is a slow, irregular rhythm with wide QRS complexes of varying morphology. This rhythm is usually seen in the late stages of unsuccessful resuscitation attempts. Agonal rhythms are not considered lethal arrhythmias as the myocardial tissue is dying and there is no treatment.

The QRS complexes become wider and wider and eventually the rhythm deteriorates into asystole. The patient is unconscious, apneic, and pulseless.



Nursing Priorities

An agonal rhythm is generally seen at the end of an unsuccessful code or when a patient has a “Do Not Resuscitate” order.

Nursing priorities generally include:

- **Considering termination of efforts.**
- **Providing patient comfort measures as needed.**
- **Family support.**

Transcutaneous Pacing

Transcutaneous pacing can be used to stimulate cardiac activity during a code. During transcutaneous pacing, an electrical current is passed through an electrode placed on the skin of the chest to stimulate electrical activity in the heart.

There are other means of “pacing” the heart available, but this approach is the quickest and most readily available in a crisis situation. Most defibrillators have a pacing capability built into them. If not, a separate transcutaneous pacemaker may be available. Learn about the pacing capabilities on your floor prior to a code.

Regardless of the brand of transcutaneous pacer used, there are several key facts to keep in mind when attempting transcutaneous pacing:

- Consider sedation as the procedure may be uncomfortable
- External pacing causes the muscles of the body to contract in addition to stimulating the cardiac myocardium. Cardiopulmonary monitoring is unreliable as interference from the muscle contractions will show on the cardiopulmonary monitor.
- Clean and dry skin is necessary under each of the “pads” used to pace in order to assure adequate conduction whenever possible

- The demand mode of pacing is used most often. If the demand mode is used, the pacer only stimulates the heart if the rate falls below a certain preset point.
 - The QRS will look wide and bizarre as it is being stimulated outside of the normal pathway.
- Assess your patient to be certain that the electrical conduction is followed by the mechanical action of the heart, thereby causing a pulse and blood pressure. Although a pacer spike may be observed on the cardiac monitor, you must check the patient to confirm that there is capture (electrical stimulation and muscle contraction).

A Case to Remember

The following story appears in “Meltzer’s Intensive Coronary Care: A Manual for Nurses” written by Kathleen Dracup (1995).

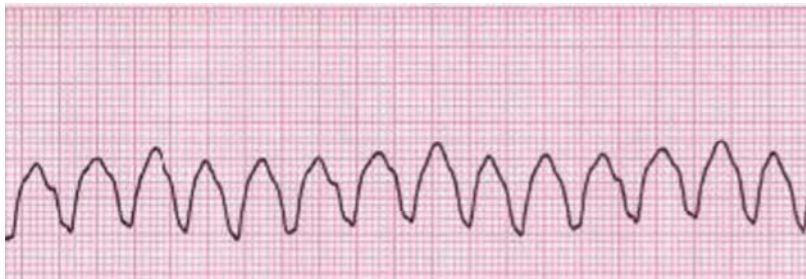
The following case history describes the first instance of lifesaving defibrillation performed by a nurse in the absence of a physician. This event took place in 1963 and became the precedent for the now established practice of defibrillation by nurses.

“A 72-year-old male was admitted to the CCU of the Presbyterian-University of Pennsylvania Medical Center with a history of chest pain that had subsided by the time of his arrival. He had no complaints and in fact, wanted to go home. An ECG showed an AMI. The findings upon physical examination were normal and there was no evidence of complications. The patient remained in normal sinus rhythm, with a heart rate ranging from 60-74/minute. Occasional premature ventricular beats were noted.

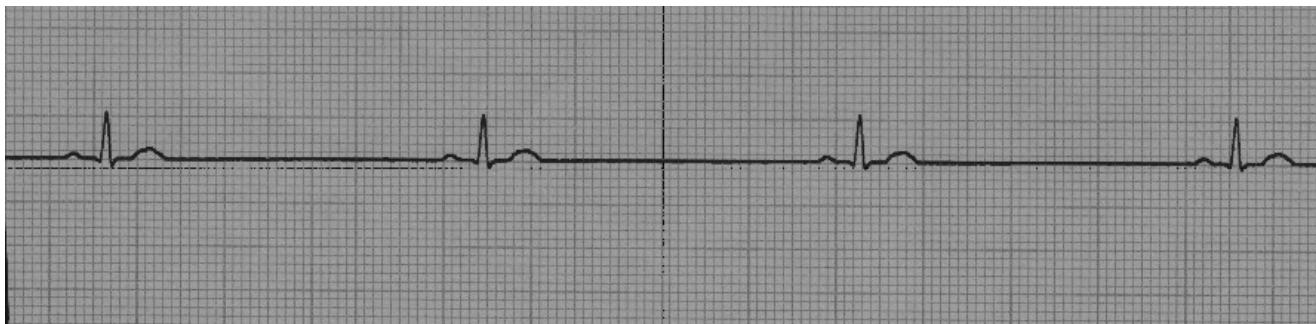
Some 60 hours after admission, in the middle of the night, the patient’s cardiac monitor alarm sounded. The nurse instantly recognized VF on the monitor and ran to the bedside, where she found the patient to be unconscious. The nurse immediately called the physician and set a timing device for 2 minutes. She turned on the defibrillator, set the energy level at 200 joules, and applied electrode paste to the defibrillator paddles. The nurse defibrillated the patient without further delay. Normal sinus rhythm was established almost immediately. The patient survived and was still alive 10 years later.” (Dracup, 1995)

Name that arrhythmia:

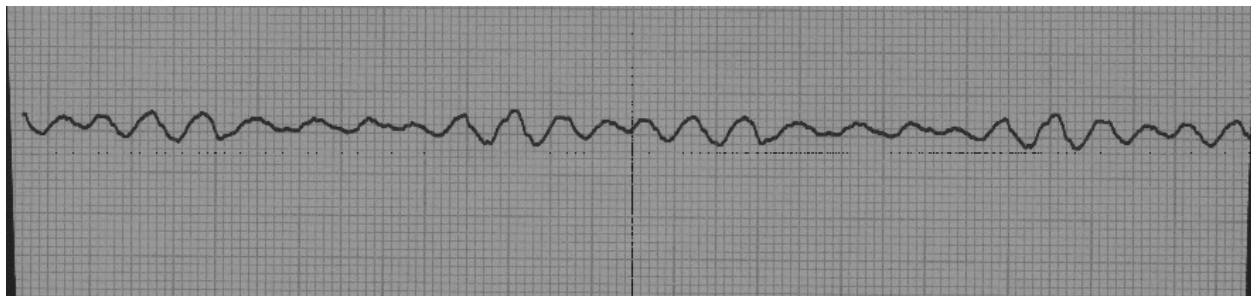
A:



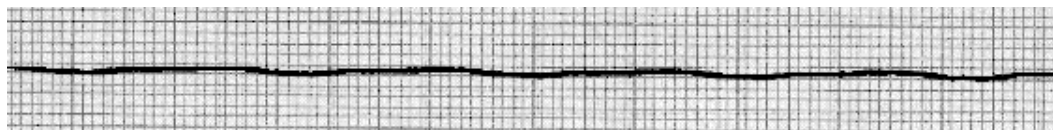
B:



C:



D:



Answers:

- a. Ventricular tachycardia
- b. Sinus bradycardia
- c. Coarse ventricular fibrillation
- d. Asystole

Critical Thinking:

1. How do you know the difference between asystole and fine ventricular fibrillation?

You need to check the arrhythmia in two leads to determine if the rhythm is shockable. Asystole is not shockable.

2. How do you know if sinus bradycardia or ventricular tachycardia is a lethal arrhythmia?

Check for a pulse.

Conclusion

Lethal arrhythmias can occur anytime; rapid nursing assessment and intervention can result in a successful outcome. Quick recognition of lethal arrhythmias and strong working knowledge of up-to-date treatment will lead to the best outcomes.

Your patient may or may not be symptomatic. However, decreased filling time and decreased stroke volume leads to decreased cardiac output in many of the tachy arrhythmias; especially those that go undetected for long periods of time. Decreased cardiac output will lead to decreased perfusion to the vital organs.

References

At the time this course was constructed all URL's in the reference list were current and accessible. rn.com. is committed to providing healthcare professionals with the most up to date information available.

© Copyright 2015, AMN Healthcare, Inc.

- American Heart Association. (2011). Advanced Cardiovascular Life Support: Professional Provider Manual.
- Kee, J.F., Hayes, E. R. & McCuiston, L. E. (2009). Pharmacology, A Nursing Process Approach (6th ed.). St. Louis, MO: Saunders Elsevier.
- Lewis, S. L., Dirksen, S., Heitkemper, M., Bucher, L. & Camera, I. M. (2011). Medical Surgical Nursing 8th Edition (pp. 301-325; 820-836). St. Louis, MO: Mobsy, Inc., an affiliate of Elsevier Inc..
- Marzlin, K. M. & Webner, C. L. (2006). Cardiovascular Nursing: A Comprehensive Overview (1st ed.). Brockton, MA: Western Schools.
- Patterson, E. & Scherlag, B.F. (2006). Decremental conduction in the posterior and anterior AV nodal inputs. *Journal of Interventional Cardiac Electrophysiology*, 7(2). 137-148.
Doi:[10.1023/A:1020833604423](https://doi.org/10.1023/A:1020833604423)

Please Read:

This publication is intended solely for the use of healthcare professionals taking this course, for credit, from RN.com. It is designed to assist healthcare professionals, including nurses, in addressing many issues associated with healthcare. The guidance provided in this publication is general in nature, and is not designed to address any specific situation. This publication in no way absolves facilities of their responsibility for the appropriate orientation of healthcare professionals.

Hospitals or other organizations using this publication as a part of their own orientation processes should review the contents of this publication to ensure accuracy and compliance before using this publication. Hospitals and facilities that use this publication agree to defend and indemnify, and shall hold RN.com, including its parent(s), subsidiaries, affiliates, officers/directors, and employees from liability resulting from the use of this publication. The contents of this publication may not be reproduced without written permission from RN.com.